

Applying the Glenoid Track Concept in the Management of Patients with Anterior Shoulder Instability

Amit M. Momaya¹ · John M. Tokish¹

© Springer Science+Business Media, LLC 2017

Abstract

Purpose of Review The purpose of this paper is to evaluate the recent evolution in the treatment of anterior shoulder instability and the dynamic interaction between the glenoid and Hill-Sachs lesion.

Recent Findings Through the glenoid track concept, glenoid- and humeral-sided bone loss are evolving away from being approached as separate entities. Recent cadaveric studies have validated the glenoid track concept. Moreover, a recent clinical study has demonstrated a much higher rate of failure after arthroscopic Bankart repair for shoulders that were off track.

Summary The glenoid track concept is a useful tool in evaluating patients with anterior shoulder instability. Shoulders that are off track may require more than a simple arthroscopic Bankart, and the addition of a remplissage or bony transfer may be considered.

Keywords Shoulder instability · Glenoid track · Bipolar lesion · Hill-Sachs lesion · Glenoid bone loss

Introduction

The management of patients with anterior shoulder instability continues to evolve. Historically, the emphasis was placed on glenoid bone loss, and it was accepted that patients with

greater than 20–25% bone loss should be addressed with the transfer of a bony block, such as a Latarjet procedure [1]. However, it is also known that a Hill-Sachs lesion is a risk factor for recurrent anterior shoulder instability. Although both glenoid-sided and humeral-sided bone loss were recognized to play a role in anterior shoulder instability, they were generally addressed as separate entities. Recently, there has been an improved understanding of the role of humeral-sided bone loss and how it dynamically interacts with glenoid-sided bone loss via the glenoid track concept [2••].

When a shoulder dislocates anteriorly, it can often impact the anterior glenoid leading to bone loss. Itoi et al. [1] helped us understand the importance of the bony defect on the glenoid side in shoulder stability. The authors performed a cadaveric study in which they tested the peak force needed for anterior translation in shoulders. They then created sequentially larger glenoid osseous defects and found that the translation force in shoulders with a 21% glenoid defect or larger was significantly lower than that in shoulders without an osseous defect. This study highlights the importance of the integrity of the anterior glenoid and its relation to instability. Burkhart and De Beer [3] introduced the concept of the inverted pear—that is, with increasing bone loss of the anteroinferior glenoid, the normal pear-shaped glenoid would invert, with the inferior half of the glenoid becoming narrower than the superior half. In their study, they recognized that after arthroscopic Bankart repairs, those patients with significant bone loss had greater recurrence rates (67%) compared to those without significant bone defects (4%). They concluded that for patients with significant bone loss, physicians should consider alternative procedures to arthroscopic repair such as a bony transfer to the glenoid to decrease failure and improve function.

When a shoulder dislocates anteriorly, the posterolateral aspect of the humeral head often impacts the anterior glenoid,

This article is part of the Topical Collection on *Management of Anterior Shoulder Instability*

✉ John M. Tokish
Jtoke95@aol.com

¹ Steadman Hawkins Clinic of the Carolinas, 200 Patewood Drive, Suite C100, Greenville, SC 29615, USA

resulting in an impaction fracture termed a Hill-Sachs lesion (Fig. 1) [4]. Sekiya et al. [5] evaluated the importance of humeral head defects in a cadaveric model. The authors demonstrated that the size and orientation of the Hill-Sachs lesion affected the stability of the shoulder joint. Specifically, they were able to show that defects as small as 12.5% may affect biomechanical stability. Furthermore, they appreciated the concept of the engaging Hill-Sachs, one that they defined as a lesion on the humeral side that engages the anterior glenoid in an overhead position with the arm abducted to 90 degrees and external rotation of any extent.

Glenoid Track Concept

Yamamoto et al. [6] introduced the concept of the glenoid track, which helps us understand the dynamic interaction between bony lesions on the glenoid and humeral head. Using a cadaveric model, the authors demonstrated that the glenoid track is equivalent to approximately 84% of the width of the normal glenoid taking account that 16% is for the rotator cuff insertion. Any bony defects in the anterior glenoid would further decrease this glenoid track width. If the medial portion of a Hill-Sachs lesion is more medial than the glenoid track, the shoulder is considered off track, and the authors suggest that an arthroscopic Bankart repair may not restore shoulder stability.

This glenoid track concept was then further evaluated in a cadaveric study using three-dimensional (3Ds) modeling by Arciero and colleagues [7•]. The authors used cadaveric shoulders and created Bankart lesions in each shoulder, which were then repaired using sutures through transosseous tunnels. Two Hill-Sachs lesions based on volume, small (25th percentile) and medium (50th percentile), were created using 3D computed tomography scans of 142 consecutive patients with recurrent instability. In addition, glenoid defects of 2, 4, and 6 mm were also made. The force required for translation was evaluated for intact specimens and those with various

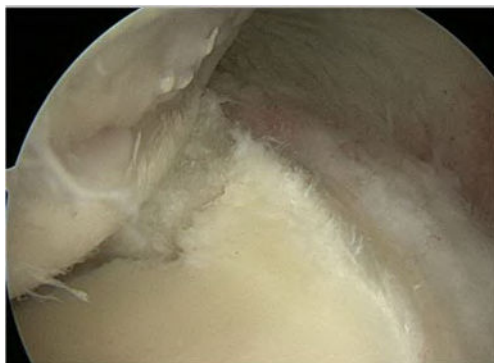


Fig. 1 An intraoperative arthroscopic picture demonstrating a Hill-Sachs lesion

combinations of humeral- and glenoid-sided bone lesions. It was shown that a 2-mm glenoid bony defect with a medium sized Hill-Sachs lesion and a 4-mm glenoid bony defect with a small sized Hill-Sachs lesion significantly reduced the forces for translation after Bankart repair, thus providing some insight into the dynamic interaction between humeral- and glenoid-sided bone loss that is both additive and negative on shoulder stability.

In another cadaveric study that sought to validate the glenoid track concept [8], the authors used eight cadaver shoulders. Glenoid bone loss was created to equate to 15% and coupled with on-track (15%) or off-track (30%) Hill-Sachs lesions. The shoulders underwent stabilization using a Bankart repair only versus a Bankart repair with remplissage. The shoulders were then placed through a custom apparatus with progressive translation loading in mid-range and end-range external rotation. The results showed that Bankart repair prevented engagement in all on-track lesions, while Bankart repair prevented engagement only in 6 (75%) at end-range rotation in off-track lesions. The addition of remplissage prevented engagement in all of these shoulders but resulted in supraphysiological stiffness for off-track lesions at mid- and end-range rotation. Thus, the results of this cadaveric biomechanical study further support the glenoid track model and the interactive role between glenoid bone loss and Hill-Sachs lesions.

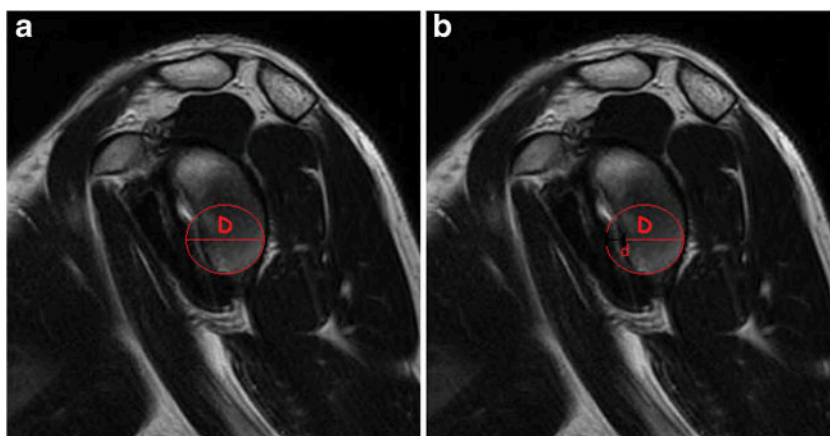
In order to measure the glenoid track, the diameter (D) of the inferior glenoid should be measured on advanced imaging. A circle can be drawn along the inferior glenoid to obtain the D (Fig. 2). The width of the anterior glenoid bone loss should then be measured (d). Multiplying the D by 0.83 and then subtracting any anterior glenoid bone loss will provide the width of the glenoid track (GT) ($GT = 0.83D - d$). Although Yamamoto originally described the glenoid track as 84% of the width, a more recent study [9] using a motion analysis system on healthy volunteers reported the glenoid track to be 83% of glenoid width, which is the number more commonly utilized. Then, the Hill-Sachs interval should be calculated, which is the width of the actual Hill-Sachs (HS) lesion plus the bony bridge from the lateral most aspect of the HS to the rotator cuff insertion. This results in the Hill-Sachs interval (HSI) (Fig. 3). If the $HSI > GT$, the shoulder is off track while if the $HSI < GT$, the shoulder is on track.

Clinical Case

The following clinical case helps illustrate how to measure the glenoid track and determine which surgical procedure may help restore stability.

The patient is a 21-year-old collegiate football player who has sustained two anterior shoulder dislocations during games requiring formal reductions. His first dislocation occurred

Fig. 2 A sagittal cut on an MRI of the shoulder depicting anterior glenoid bone loss. **a** “D” signifies the diameter of the circle drawn along the inferior glenoid. **b** “d” signifies the distance of anterior bone loss



midseason, and the athlete was able to return to play. However, he sustained a recurrent dislocation at the end of the season and now wishes for surgical intervention. An MRI was obtained for further evaluation. Figure 2a demonstrates the measurement of the diameter (*D*) of the inferior glenoid on a sagittal image using a perfect circle, which was measured to be 29.1 mm. Next, the width of the anterior glenoid bone loss (*d*) was measured to be 6.5 mm, as shown in Figure 2b. The HSI was then measured to be 21.1 mm on an axial image (Figure 3). Thus, the glenoid track was calculated as follows: $GT = 0.83(29.1) - 6.5 = 17.7$ mm. This is then compared to the HSI of 21.1 mm. Because the $GT < HSI$, this patient’s shoulder is considered “off track.” We thus decided to proceed with a Latarjet procedure.

Measurements for glenoid track and Hill-Sachs measurements were originally described using 3D CT. However, 3D CT scans are not always available, prompting an investigation into alternative advanced imaging. Gyftopoulos et al. [10] utilized MRI to evaluate whether shoulders were on track or off track. They then compared this to intraoperative arthroscopy findings and any evidence of engagement. The overall

accuracy of MRI to predict off track or on track was 84%. Thus, MRI serves as an acceptable imaging modality in evaluating whether a shoulder is on track or off track. In another study [11], authors evaluated whether a 2D shoulder CT would be accurate in predicting engagement. The authors created various bipolar lesions in cadaveric specimens and initially classified them as on track or off track based upon 3D scans. Then, the shoulders were evaluated with an abduction and external rotation (ABER) CT view with the shoulder in 60 degrees of abduction and 90 degrees of external rotation. This method accurately predicted engagement in 96% of shoulders with sensitivity and specificity of 92 and 100%, respectively. An alternative method is using the intact anterior articular angle (IAAA), defined as the angle between the anterior margin of the humeral head articular surface and the medial margin of the Hill-Sachs lesion, was investigated. A logistic regression was employed to produce a model that predicted engagement based upon IAAA (Fig. 4) and glenoid defect width. The model fit was shown to be very good with an

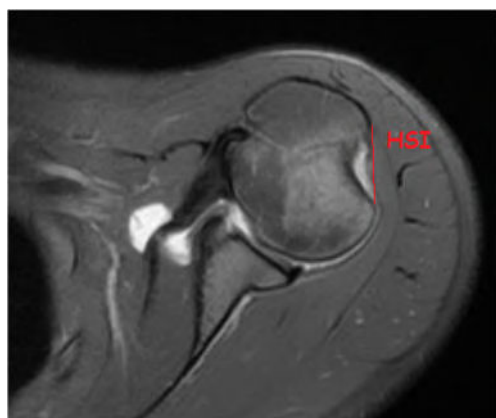

Fig. 3 An axial cut on an MRI of the shoulder demonstrating the Hill-Sachs interval (HSI) from the medial most portion of the Hill-Sachs lesion to the insertion of the rotator cuff tendon

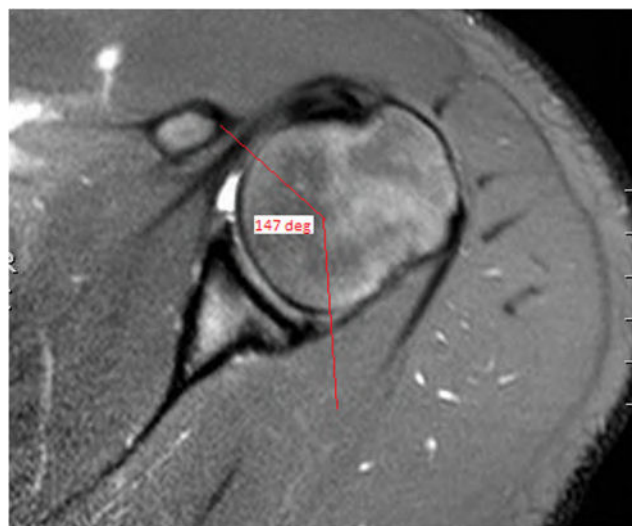


Fig. 4 An axial cut on a shoulder MRI shows the measurement of the intact anterior articular surface (IAAA)

accuracy of 87%. Thus, surgeons may use either MRI or 2D CT scans to help classify whether the lesion is on track or off track when 3D CT scans are not available.

Despite these studies, a recent study [12] has called into question the reliability and reproducibility of measuring the glenoid track width and Hill-Sachs interval. The authors evaluated 3D CT scan for 71 patients. En face views of the glenoid fossae and three views of the humeral head were obtained. Four different physicians were the assessors. There was good interobserver and intraobserver agreement for glenoid bone loss. However, there was poor interobserver reliability for on-track versus off-track classification. The coefficient of variability for the Hill-Sachs lesion was 19.2% compared to < 4% for all other measurements. Thus, although glenoid bone loss can be measured reliably and reproducibly, there is high variability with poor interobserver reliability in the measurement of the Hill-Sachs lesion.

Clinical Application

Metzger et al. [13] sought to correlate radiographic findings of “on track” or “off track” with clinical findings. Clinically, patients were classified as “off track” if the Hill-Sachs was found to engage with physical examination under anesthesia and seen to engage with initial diagnostic arthroscopic video. Of the 19 patients with suggested radiographic engagement, 16 or 85% had clinical evidence of engagement. Both younger age and a greater number of recurrence events were predictive of radiographic off track or engagement. This study demonstrated that preoperative radiographic measurements of the glenoid and humeral head bone loss to calculate the glenoid track were successful at predicting Hill-Sachs engagement clinically.

However, it was not until recently that the glenoid track concept was clinically validated. Tokish and colleagues [14••] evaluated whether glenoid track measurements would predict outcomes after arthroscopic Bankart repairs. Preoperative magnetic resonance imaging was used to determine if the lesions were “on track” or “off track”. Fifty-seven shoulders were treated with arthroscopic Bankart repair alone and followed for a mean time of 48 months. Of the 49 “on-track” patients, 4 (8%) had recurrence of instability compared to 6 of 8 “off-track” patients ($P = 0.0001$). The authors found that the positive predictive value for recurrence of an off-track measurement was 75%. This value is higher than the 44% predictive value based upon glenoid bone loss > 20% alone. Thus, this study highlights the importance of the glenoid track and its ability to predict patients that may have recurrent instability. Such patients should be considered for alternative surgical management options such as glenoid augmentation with bony block or a remplissage in addition to the arthroscopic Bankart repair. Similarly, Imhoff and colleagues [15] evaluated whether off-track lesions result in more frequent revision surgery for recurrent instability. Of 100 patients who underwent arthroscopic Bankart repair, revision surgery was performed in 5 patients (6%) with an “on-track” lesion versus 4 patients (33%) who had an “off-track” lesion (odds ratio = 8.3, $P = .006$). However, the study was limited because several patients may have been lost as the authors evaluated only those needing revision. It is feasible that there may have been others who failed and sought care at other medical centers.

Another study [16] recently has looked at whether a shoulder is “on track” or “off track” postoperatively after a Latarjet procedure and its utility in predicting postoperative failure. The authors combined the native glenoid width with the coracoid width to define the glenoid track. They found that off-track lesions were 4.0 times more likely to experience

Table 1 Comparisons of the two Latarjet techniques [18, 19]

Latarjet procedure	Advantages	Disadvantages
Traditional	Larger surface area for healing Greater bone width for screw placement Superior initial fixation	Does not match the radius of curvature of anterior inferior glenoid—may need to recess or burr down prominences Increased contact pressures and edge loading Potential increases risk in future arthritis
Congruent arc	Similar radius of curvature to anterior inferior glenoid Decreased glenohumeral contact pressures and edge loading Potential decreased risk in future arthritis Allows restoration of a larger glenoid defect	Decreased surface area—potential increased nonunion risk Decreased bone width for screws—potential for graft fracture

postoperative instability ($P = .033$). Furthermore, the width of the coracoid process correlated with postoperative stability ($P = .014$). Thus, surgeons should carefully evaluate whether a coracoid transfer will result in an “on-track” shoulder. If not, one may need to consider the addition of an arthroscopic remplissage prior to the Latarjet or seek alternative bony grafts that provide a greater width with which to augment the glenoid track. In fact, a recent technique article by Katthagen et al. [17] describes performing an arthroscopic remplissage prior to an open Latarjet. The authors suggest starting with the arthroscopic remplissage without tying the sutures. Leaving the suture untied may facilitate the placement of the Fukuda retractor during the Latarjet procedure. Upon completion of the Latarjet procedure, the sutures can then be tied to complete the remplissage.

In addition, recent work has been performed to evaluate differences surrounding the types of Latarjet procedure performed. The traditional Latarjet procedure entails apposition of the inferior surface of the coracoid to the anterior glenoid defect area. A modification to this technique, termed the congruent arc modification, rotates the coracoid 90 degrees so that the medial surface of the coracoid is apposed to the anterior glenoid. Table 1 lists the relative advantages and disadvantages of each technique [18, 19].

Although an off-track lesion is predictive of instability, no studies to date have directly compared addressing off-track lesions with a bony block versus arthroscopic Bankart repair with remplissage in terms of recurrent instability and patient-reported outcome scores. Future studies should clarify when an arthroscopic remplissage and/or bony block is needed.

Future Directions

The concept of the glenoid track is an important evaluation tool for anterior shoulder instability in the setting of bipolar bone loss. It is clear that this concept can be used to assist surgeons in determining which patients may not be appropriate for arthroscopic Bankart repair alone. Further work is needed to determine when to utilize a bony block or adding a remplissage procedure to the arthroscopic Bankart repair. As we gain increased understanding of the dynamic interaction between the glenoid and the Hill-Sachs lesion, patient care will further be individualized to maximize patient-reported outcomes and decrease recurrent instability after surgery.

Compliance with Ethical Standards

Conflict of Interest Both authors declare that they have no conflict of interest.

Human and Animal Rights and Informed Consent This article does not contain any studies with human or animal subjects performed by any of the authors.

References

Papers of particular interest, published recently, have been highlighted as:

- Of importance
- Of major importance

1. Itoi E, Lee SB, Berglund LJ, Berge LL, An KN. The effect of a glenoid defect on antero-inferior stability of the shoulder after bankart repair: a cadaveric study. *J Bone Joint Surg Am*. 2000;82: 35–46.
2. Di Giacomo G, Itoi E, Burkhart SS. Evolving concept of bipolar bone loss and the Hill-Sachs lesion: from “engaging/non-engaging” lesion to “on-track/off-track” lesion. *Arthroscopy*. 2014;30:90–8. **Excellent review and explanation of the glenoid track concept. Illustrations help the reader understand how to calculate and visualize whether the shoulder is on track or off track.**
3. Burkhart SS, De Beer JF. Traumatic glenohumeral bone defects and their relationship to failure of arthroscopic Bankart repairs: significance of inverted-pear glenoid and the humeral engaging Hill-Sachs lesion. *Arthroscopy*. 2000;16:677–94.
4. Hill HA, Sachs MD. The grooved defect of the humeral head: a frequently unrecognized complication of the shoulder joint. *Radiology*. 1940;35:690–700.
5. Sekiya JK, Wickwire AC, Stehle JH, Debski RE. Hill-Sachs defects and repair using osteoarticular allograft transplantation: biomechanical analysis using a joint compression model. *Am J Sports Med*. 2009;37:2459–66.
6. Yamamoto N, Itoi E, Abe H, Minagawa H, Seki N, Shimada Y, et al. Contact between the glenoid and the humeral head in abduction, external rotation, and horizontal extension: a new concept of glenoid track. *J Shoulder Elb Surg*. 2007;16:649–56.
7. Arciero RA, Parrino A, Bernhardtson AS, Diaz-Doran V, Obopilwe E, Cote MP, et al. The effect of a combined glenoid and Hill-Sachs defect on glenohumeral stability: a biomechanical cadaveric study using 3-dimension modeling of 142 patients. *Am J Sports Med*. 2015;43:1422–9. **Recent cadaveric study demonstrating how various sizes of glenoid-and humeral-sided bone loss interact and lead to recurrent instability.**
8. Hartzler RU, Bui CN, Jeong WK, Akeda M, Peterson A, McGarry M, et al. Remplissage of an off-track Hill-Sachs lesion is necessary to restore biomechanical glenohumeral joint stability in a bipolar bone loss model. *Arthroscopy*. 2016;32:2466–76.
9. Omori Y, Yamamoto N, Koishi H, Futai K, Goto A, Sugamoto K, et al. Measurement of the glenoid track in vivo as investigated by 3-dimensional motion analysis using open MRI. *Am J Sports Med*. 2014;42:1290–5.
10. Gyftopoulos S, Beltran LS, Bookman J, Rokito A. MRI evaluation of bipolar bone loss using the on-track off-track method: a feasibility study. *AJR Am J Roentgenol*. 2015;205:848–52.
11. Burns DM, Chahal J, Shahrokhi S, Henry P, Wasserstein D, Whyne C, et al. Diagnosis of engaging bipolar bone defects in the shoulder using 2-dimensional computed tomography: a cadaveric study. *Am J Sports Med*. 2016;44:2771–7.
12. Schneider AK, Hoy GA, Ek ET, Rotstein AH, Tate J, Taylor DM, et al. Interobserver and intraobserver variability of glenoid track measurements. *J Shoulder Elb Surg*. 2017;26:573–9.
13. Metzger PD, Barlow B, Leonardelli D, Peace W, Solomon DJ, Provencher MT. Clinical application of the “glenoid track” concept for defining humeral head engagement in anterior shoulder instability: a preliminary report. *Orthop J Sports Med*. 2013. <https://doi.org/10.1177/2325967113496213>.
14. Shaha JS, Cook JB, Rowles DJ, Bottoni CR, Shaha SH, Tokish JM. Clinical validation of the glenoid track concept in anterior

- glenohumeral instability. *J Bone Joint Surg Am.* 2016;98:1918–23. **This is the first paper to clinically validate the glenoid track concept. Those patients who underwent arthroscopic Bankart repair and were off track had a significantly higher chance for recurrent instability when compared to those patients that were on track.**
15. Locher J, Wilken F, Beitzel K, Buchmann S, Longo UG, Denaro V, et al. Hill-Sachs off-track lesions as risk factor for recurrence of instability after arthroscopic Bankart repair. *Arthroscopy.* 2016;32:1993–9.
 16. Mook WR, Petri M, Greenspoon JA, Horan MP, Dornan GJ, Millett PJ. Clinical and anatomic predictors of outcomes after the Latarjet procedure for the treatment of anterior glenohumeral instability with combined glenoid and humeral bone defects. *Am J Sports Med.* 2016;44:1407–16.
 17. Katthagen JC, Anavian J, Tahal DS, Millett PJ. Arthroscopic remplissage and open Latarjet procedure for the treatment of anterior glenohumeral instability with severe bipolar bone loss. *Arthrosc Tech.* 2016;5:e1135–41.
 18. Montgomery SR, Katthagen JC, Mikula JD, Marchetti DC, Tahal DS, Dornan GJ, et al. Anatomic and biomechanical comparison of the classic and congruent arc techniques of the Latarjet procedure. *Am J Sports Med.* 2017;45:1252–60.
 19. Dumont GD, Vopat BG, Parada S, Cohn R, Makani A, Sanchez G, et al. Traditional versus congruent arc Latarjet technique: effect on surface area for union and bone width surrounding screws. *Arthroscopy.* 2017;33:946–52.