

Delayed Presentation of a Cervical Spine Fracture Dislocation With Posterior Ligamentous Disruption in a Gymnast

Amit Momaya, MD, Curtis Rozzelle, MD, Kenny Davis, ATC, LAT, and Reed Estes, MD

Abstract

Cervical spine injuries are uncommon but potentially devastating athletic injuries. We report a case of a girl gymnast who presented with a cervical spine fracture dislocation with posterior ligamentous disruption several days after injury. To our knowledge, this type of presentation with such severity of injury in a gymnast has not been reported in the literature.

The patient was performing a double front tuck flip and sustained a hyperflexion, axial-loading injury. She experienced mild transient numbness in her bilateral upper and lower extremities lasting for about 5 minutes, after which it resolved. The patient was neurologically intact during her clinic visit, but she endorsed significant midline cervical tenderness. Plain radiographs and computed tomography imaging of the cervical spine revealed a C2-C3 fracture dislocation. She underwent posterior open reduction followed by C2-C3 facet arthrodesis and internal fixation.

This case highlights the importance of very careful evaluations of neck injuries and the maintenance of high suspicion for significant underlying pathology.

According to the patient, she had been performing a double front tuck flip and landed directly on her head with an axial-loading hyperflexion injury mechanism. Specifically, she was running on a standard gymnastics spring floor before proceeding into a double front tuck flip. She did not use any accessory spring board or trampoline to elevate herself. She landed head first onto a standard 8-in gymnastics mat. The patient thought that she had not achieved enough rotation in the air. She had successfully landed this maneuver into a foam pit, but this was her first attempt at trying to land on a mat. Although a coach was present in the area, she was not spotting the patient during the accident. Of note, the patient had achieved a level 8 on the USA Gymnastics developmental level scale; she was attempting a gymnastics maneuver intended for higher level gymnasts. Immediately after her injury, the patient experienced substantial midline upper cervical pain. In addition, she experienced mild transient numbness in her bilateral upper and lower extremities lasting for about 5 minutes, after which it resolved. She denied loss of consciousness or blurry vision.

The patient began wearing a soft cervical collar shortly after the injury as a result of continued neck pain. The next day, she saw the onsite athletic trainer for evaluation and was urged to wear the collar until she was assessed by a physician. At the sports medicine clinic, the patient said that cervical pain continued to be her only symptom. Evaluation showed significant upper cervical midline and paraspinal tenderness to palpation. Her neurologic examination revealed full strength and sensation intact to light touch in her bilateral upper and lower extremities. Reflexes were symmetric, and no upper motor neuron signs were present.

Plain anteroposterior and lateral radiographs of the cervical spine showed significant anterolisthesis of C2 on C3 (Figures 1A, 1B). Because of concern about a fracture dislocation and ligamentous disruption, the patient was placed in an Aspen collar. A computed tomography (CT) scan of the cervical spine, obtained the same day, confirmed anterolisthesis of C2 on C3 and showed a left-sided jumped facet and a right-sided perched C2-C3 facet with a chip fracture of the anterosuperior C3 facet (Figures 2A, 2B).

Magnetic resonance imaging (MRI) of the cervical spine, obtained the next day for preoperative planning, also showed

Cervical spine injuries are uncommon but potentially devastating athletic injuries. In particular, gymnastics requires incredible flexibility and proprioception, and the sport can place the spine in a very precarious position. With the growth of gymnastics, especially in the pediatric population, safety is very important.

We report a case of a girl gymnast who presented with a cervical spine fracture dislocation with posterior ligamentous disruption several days after injury. The patient's guardian provided written informed consent for print and electronic publication of this case report.

Case Report

A 10-year-old girl gymnast presented to the sports medicine clinic 4 days after injury complaining of upper cervical neck

Authors' Disclosure Statement: The authors report no actual or potential conflict of interest in relation to this article.

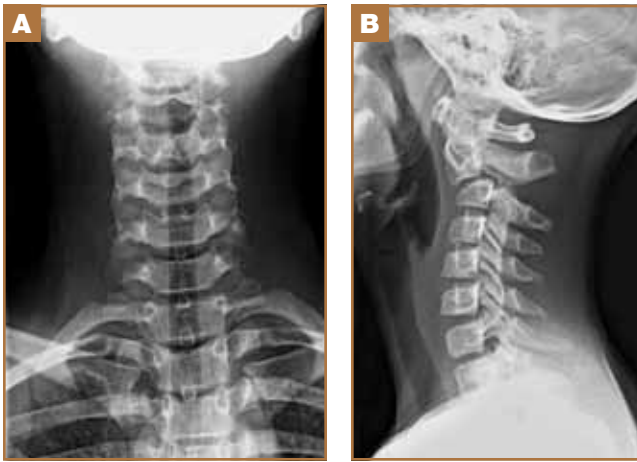


Figure 1. (A) Anteroposterior view of cervical spine. (B) Lateral view of cervical spine shows anterolisthesis of C2 on C3.

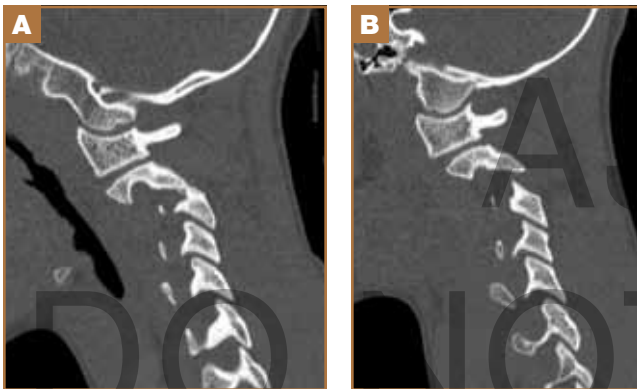


Figure 2. (A) CT scan of cervical spine shows left-sided jumped facet of C2-C3. (B) CT scan of cervical spine shows right-sided perched facet of C2-C3.

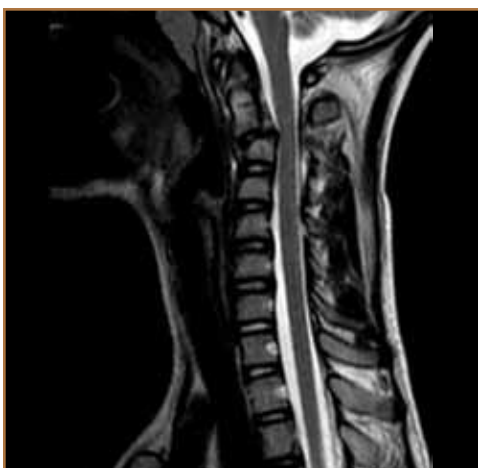


Figure 3. MRI of cervical spine shows severe spinal canal stenosis from the disruption of the C2-C3 intervertebral disc.

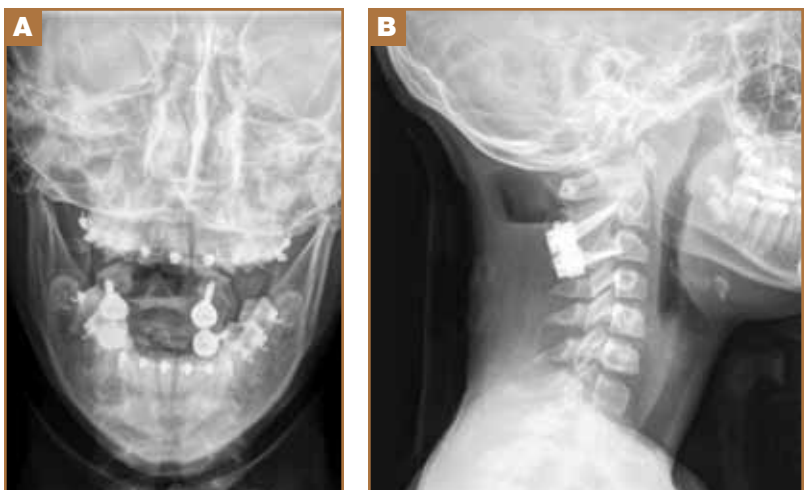


Figure 4. (A) Anteroposterior view of cervical spine postoperatively. (B) Lateral view of cervical spine postoperatively.

the anterolisthesis with disruption of the C2-C3 intervertebral disc, causing moderate to severe spinal stenosis with an associated subtle T2 hyperintensity in the spinal cord (Figure 3). The spinal canal measured approximately 7.0-mm anterior-posterior. Imaging also showed disruption of the posterior longitudinal, interspinous, and supraspinous ligaments. In addition, marrow edema present in C3 was consistent with an anterior compression fracture.

The next day, the patient underwent posterior open reduction of the C2-C3 fracture dislocation followed by C2-C3 facet arthrodesis and internal fixation with bilateral C2 pars and C3 lateral mass screws (Figures 4A, 4B). She did not experience any complications and was neurologically intact postoperatively.

At her 4-month postoperative visit, the patient was doing well and had no complaints. She demonstrated full range of motion of her neck without any discomfort, and her neurologic exam revealed no deficits. Flexion and extension radiographs of the cervical spine showed a stable, mature fusion without evidence of instability (Figures 5A, 5B). The patient was cleared to resume her usual activities; however, she and her family, concerned about the potential for more injuries, have decided that she will no longer compete in gymnastics.

Discussion

The incidence and location of injuries in gymnastics is well documented.¹ The most frequently injured portion of the spine is the lower back, accounting for about 12% of all injuries sustained by gymnasts. Much of the focus on spine injuries has been placed on chronic or fatigue injuries, with the differential including spondylolysis, Scheuermann disease, intervertebral disc pathology, and mechanical sources of pain.²

Although injuries to the cervical spine in gymnasts are rare, they can occur and the consequences can be devastating. The cervical spine is the most common level of injury in acute spi-

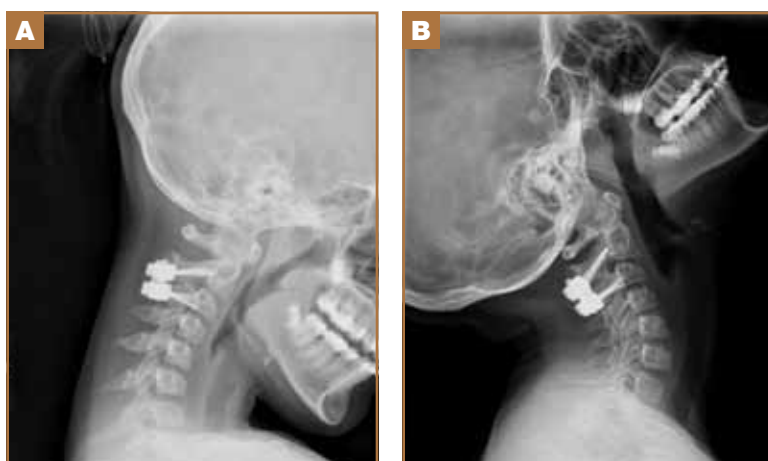


Figure 5. (A) Flexion view of cervical spine shows stability. (B) Extension view of cervical spine shows stability.

nal cord injuries. Schmitt and colleagues³ identified 6 gymnasts with acute spinal cord injuries; all were cervical. Silver and colleagues⁴ found 38 gymnasts with acute spinal injuries, of which 35 occurred in the cervical region.

The mechanism of cervical spine injury is often a significant axial load. Flexion during these injuries disproportionately distributes the stress to the cervical spine; such a mechanism explains the injury sustained by our patient.

According to Keller,⁵ the athlete who sustains a spinal injury is generally a gymnast at an elite or highly competitive level; spinal cord injury in the recreational athlete is extremely rare. In addition, the gymnast is rarely at ground level but is employing a spring board or a trampoline to increase potential energy. Our patient was a highly competitive gymnast, who used only a spring mat to help elevate herself.

A thorough characterization of the type of cervical injuries has not been developed because of the rarity of cervical spine injuries in gymnasts. With increasing emphasis on sports, especially gymnastics, it will be important to study cervical injuries sustained by these athletes to increase awareness and improve their treatment.

Any athlete who experiences a fall onto his or her head should have a thorough evaluation, including a comprehensive neurologic examination. Any midline or paraspinous ten-

erness to palpation should be elicited. Patients with neurologic symptoms and this mechanism of injury should be regarded as having a cervical spine injury until proved otherwise. They should be placed in a rigid cervical collar and transported to a hospital, where imaging, starting with plain radiographs, should be performed. Patients with neck pain but no neurologic symptoms can be dismissed as having neck strains, but it is important to rule out a more significant injury, such as a fracture or spinal cord compression, with imaging.

Conclusion

We have described an axial-loading hyperflexion injury to the cervical spine, resulting in a fracture dislocation with spinal cord impingement in a child gymnast. To our knowledge, this type of presentation with such severity of injury in a gymnast has not been reported in the literature.

This case highlights the importance of very careful evaluations of neck injuries and the maintenance of high suspicion for significant underlying pathology.

Dr. Momaya is Orthopedic Resident, Dr. Rozzelle is Assistant Professor of Neurosurgery, Mr. Davis is Athletic Trainer, and Dr. Estes is Assistant Professor of Orthopedic Surgery, University of Alabama at Birmingham, Birmingham, Alabama.

Address correspondence to: Reed Estes, MD, University of Alabama at Birmingham Sports Medicine, 1600 7th Ave. South, ACC 402, Birmingham, AL 35233 (tel, 205-638-2328; fax, 205-638-6049; e-mail, aestes@uabmc.edu)

Am J Orthop. 2014;43(6):272-274. Copyright Frontline Medical Communications Inc. 2014. All rights reserved.

References

1. Caine DJ, Nassar L. Gymnastic injuries. In: Caine DJ, Maffulli N, eds. *Epidemiology of Pediatric Sports Injuries*. Basel, Switzerland: Karger; 2005:18-58. *Individual Sports*; Vol. 48.
2. Kruse D, Lemmen B. Spine injuries in the sport of gymnastics. *Curr Sports Med Rep.* 2009;8(1):20-28.
3. Schmitt H, Gerner HJ. Paralysis from sport and diving accidents. *Clin J Sport Med.* 2001;11(1):17-22.
4. Silver JR, Silver DD, Godfrey JJ. Injuries of the spine sustained during gymnastic activities. *Br Med J (Clin Res Ed).* 1986;293(6551):861-863.
5. Keller MS. Gymnastics injuries and imaging in children. *Pediatr Radiol.* 2009;39(12):1299-1306.

This paper will be judged for the Resident Writer's Award.