



# Os acromiale: systematic review of surgical outcomes

Gean C. Viner, BS, Jun Kit He, BA, Eugene W. Brabston, MD, Amit Momaya, MD, Brent A. Ponce, MD\*

*Department of Orthopaedic Surgery, University of Alabama at Birmingham, Birmingham, AL, USA*

**Background:** The literature is unclear as to the optimal surgical management of a symptomatic os acromiale that has failed nonoperative treatment. Surgical options include excision, acromioplasty, and open reduction and internal fixation. The purpose of this study is to summarize the described methods and compare their reported outcomes with the goal to provide direction on how to surgically manage os acromiale.

**Methods:** We performed a systematic review of the current medical literature. Fifteen studies met all the inclusion criteria. Two hundred eleven total subjects (220 shoulders) underwent surgical treatment for a symptomatic os acromiale. There were 140 men and 71 women with a mean age of  $49.6 \pm 9.1$  years. The mean follow-up duration was  $40 \pm 11.6$  months. Surgical techniques used in the included studies were excision, acromioplasty, and open reduction with internal fixation. Concurrent surgical procedures performed were also included.

**Results:** Meso-os acromiale was the most common type (167 cases, 94.4%). The most common surgical technique was internal fixation (135 cases, 60.8%), with screw fixation being the majority (76 cases, 56.3%). Excision (65 cases, 29.3%) was the second most used technique. The most common concurrent surgical procedure performed was rotator cuff repair (125 cases, 56.3%), followed by distal clavicle excision (31 cases, 14%).

**Conclusions:** All surgical techniques employed resulted in improvement in postsurgical clinical outcomes without any technique demonstrating superior results. Operative management of a symptomatic os acromiale that has failed initial nonoperative treatment leads to decreased symptoms and improvement in clinical outcomes.

**Level of evidence:** Level IV; Systematic Review

© 2019 Journal of Shoulder and Elbow Surgery Board of Trustees. All rights reserved.

**Keywords:** Os acromiale; acromion; nonunion; surgery; treatment; fixation; excision; repair

Institutional Review Board approval was not required for this systematic review.

\*Reprint requests: Brent A. Ponce, MD, Department of Orthopaedic Surgery, University of Alabama at Birmingham, 1313 13th Street South, Suite 203, Birmingham, AL 35205, USA.

E-mail address: [bponce@uabmc.edu](mailto:bponce@uabmc.edu) (B.A. Ponce).

An os acromiale occurs when the acromial apophysis fails to fuse with the spine of the scapula in a skeletally mature individual.<sup>29</sup> Four ossification centers (pre-, meso-, meta-, and basiacromion) develop into the acromial apophysis and failure of union can occur between any two.<sup>3</sup> Ossification failure is most common between the meso-acromion and meta-acromion.<sup>19</sup> Final maturation occurs between ages 18 and 25 years, although fusion as early as

ages 12 and 14 years is reported.<sup>29,30,33</sup> Yammine in a systematic review and meta-analysis reported the pooled prevalence in anatomical studies (7037 individuals) to be 6.4% and in large-sample studies (5498 individuals) to be 7%.<sup>32</sup>

Clinically, os acromiale is often asymptomatic and is an incidental radiographic finding. It can become symptomatic after trauma disrupting fibrous union, and magnetic resonance imaging may show inflammation at the site of nonunion.<sup>26</sup> Deltoid contraction and elevation of the arm causing motion across the interface of the os acromiale can lead to symptomatic presentation. When the condition does present, anterolateral and lateral acromiale tenderness is common.<sup>26</sup> The clinical diagnosis of a symptomatic os acromiale can often overlap with the diagnosis of subacromial impingement or acromioclavicular joint arthrosis. Symptoms of both a painful os acromiale and subacromial impingement include difficulty with overhead activities, sleeping on the affected side, rotator cuff weakness, decreased active forward elevation of the arm, and positive impingement.<sup>19</sup>

Nonoperative management is generally the first line of treatment for a symptomatic os acromiale. This includes optimization of muscular balance in the affected shoulder, corticosteroid injections (after diagnostic injection with local anesthetics), and avoidance of repetitive trauma. Injections may be done in the subacromial space or in the nonunion site of the os acromiale. Nonoperative treatment is suggested for at least 6 months before transitioning to surgery.<sup>26</sup>

There are various operative approaches described in the literature. These include open or arthroscopic fragment excision, open or arthroscopic acromioplasty, and open reduction and internal fixation.<sup>1,3,10,14,23,27,28,31</sup> The purpose of this study is to summarize the described methods and compare their reported outcomes. The goal is to provide direction on how to surgically manage os acromiale.

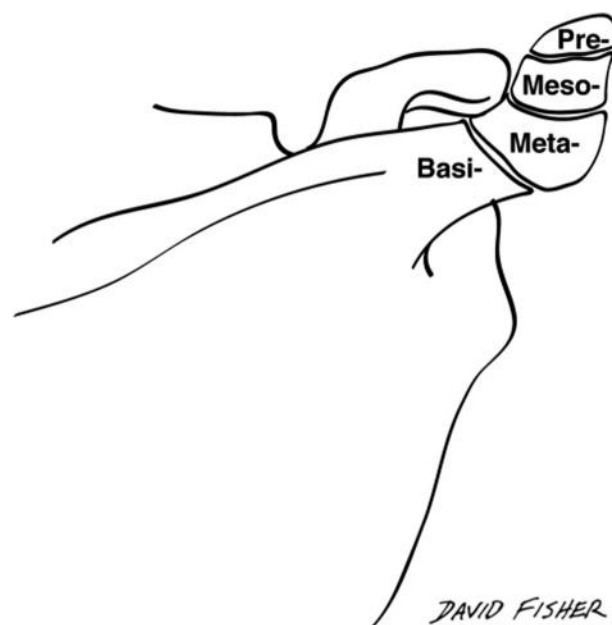
## Methods

A systematic review of the current medical literature was performed using PubMed, Scopus, Embase, EBSCO, and Google Scholar. The initial search was conducted by one of the authors with no restriction on search dates, and the search terms included *os acromiale*, *os acromial*, *os acromion*, *surgery*, *treatment*, *fixation*, *excision*, and *repair*. Published literature with these search criteria were combined in a list that was reviewed and discussed among 2 of the authors. From this list, inclusion or exclusion criteria were determined and executed to provide suitable data for review. The initial list went through multiple iterations, with each corresponding to a title review, an abstract review, and a full-text review. The reference list of the selected articles was manually reviewed for any potential studies that might not have been identified by the initial search. The inclusion criteria included being published in English, reporting of clinical outcomes following surgical treatment of symptomatic os

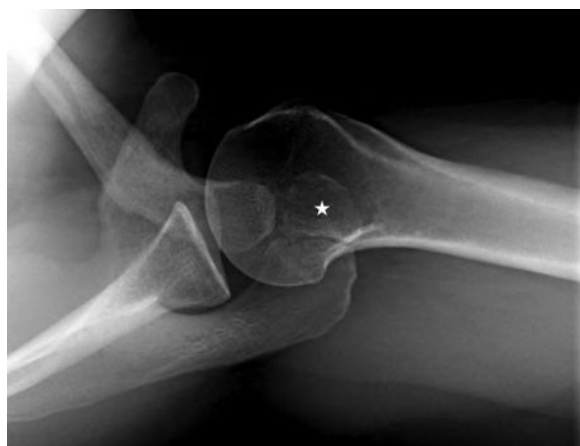acromiale, description of the surgical treatment of symptomatic os acromiale (including excision, acromioplasty, and internal fixation), and a mean follow-up of 24 months or greater. In the event of disagreement for study inclusion among authors, the inclusion criteria were reviewed, and a decision was made with discussion of the study. This systematic review of the available literature followed the Preferred Reporting Items for Systematic reviews and Meta-Analyses (PRISMA) guidelines.<sup>15,16</sup>

Initially, 33 studies were identified in PubMed, 30 in Scopus, 33 in Embase, 21 in EBSCO, and 498 in Google Scholar. These were combined, and duplicates were removed to create a list of 514 potential articles that were reviewed by 2 authors. After a title review, 57 articles were left for abstract review and subsequent full-text evaluation. Of the 57 potential studies, only 15 met all the inclusion criteria after the final assessment.<sup>1-5,7,9,12,13,20,21,24,25,29,31</sup> The exclusion criteria included non-English studies, single-patient case reports, basic science and biomechanical studies, studies that failed to report clinical outcomes after surgical treatment of symptomatic os acromiale, studies that had a mean follow-up of less than 24 months, and publications describing acromial fractures.

Classifications of os acromiale type were defined by the unfused segment immediately anterior to the site of nonunion (Figs. 1 and 2). Failure of union between the pre- and meso-acromion was classified as pre-os acromiale, failure of union between the meso- and meta-acromion was classified as meso-os acromiale, and failure of union between meta- and basi-acromion was defined as meta-os acromiale.<sup>22</sup> All of the included studies described a surgical technique for addressing a painful os acromiale. Excision was defined as complete removal of the os acromiale fragment by either open anterior approach or arthroscopic technique.<sup>5,7,9,21,29,31</sup> In comparison, acromioplasty was defined as partial or incomplete removal of the os acromiale fragment by



**Figure 1** Ossification centers. *Pre-*, pre-os acromiale; *Meso-*, meso-os acromiale; *Meta-*, meta-os acromiale; *Basi-*, basi-os acromiale.



**Figure 2** Axillary view of meso-os acromiale. ★, os acromiale fragment.

either open Neer technique or arthroscopic techniques.<sup>1,5,8,13,17</sup> Internal fixation was defined as internal placement of hardware with either Kirschner wires or screws stabilizing the os acromiale fragment to the more proximal acromion with or without the use of a tension band technique.<sup>1-5,9,12,20,24,25,29</sup> The clinical assessment tools used postsurgically included the American Shoulder and Elbow Surgeons score (ASES), the Constant score, the Penn shoulder score, and the University of California Los Angeles shoulder evaluation form (UCLA).<sup>1,3-5,7,9,12,13,20,24,25,31</sup> Additionally, multiple studies used postoperative radiographs to determine union vs. nonunion rates.<sup>1-5,9,12,20,24,25,29</sup> Only a single study reported isokinetic strength testing as its postsurgical clinical assessment.<sup>21</sup>

## Results

**Table I** shows a tabulated form of the search strategy, and the results after each search criterion was queried. Fifteen studies met all the inclusion criteria with summaries reported in **Table II**.<sup>1-5,7,9,12,13,20,21,24,25,29,31</sup> There were 211 total subjects (220 shoulders) who underwent surgical treatment for os acromiale. Among these subjects, there were 140 men and 71 women. The mean age of the participating subjects was  $49.6 \pm 9.1$  years, with a range of 18-78 years. The mean follow-up duration for the participating subjects was  $40 \pm 11.6$  months, with a range of 5-124 months. In the studies that reported handedness, the dominant shoulder was involved in 66 (66.0%) cases whereas the nondominant was involved in 34 (34.0%) cases, with 5 (5.0%) cases being bilateral.<sup>1,3,7,12,13,21,24,25</sup>

**Table III** shows the os acromiale type and the accompanying surgical technique employed for repair. Meso-os acromiale was the most common type (167 cases, 94.4%). The second most common was pre-os acromiale (7 cases, 4.0%), and the least common was meta-os acromiale (3 cases, 1.7%). Internal fixation was used in 135 cases (60.8% of treated shoulders), making it the most common surgical technique used. The screw fixation technique with

the use of 2 screws with or without tension band was employed in 76 of the internal fixation cases (56.3%). In comparison, the alternative Kirschner wire technique with the use of 2 parallel K-wires and either a stainless-steel wire or nonabsorbable suture in a figure-of-8 method was used in 59 of the internal fixation cases (43.7%). Excision (65 cases, 29.3%) was the second most commonly used technique. Lastly, acromioplasty was the least used technique, only being performed on 22 cases (9.9%).

A bone graft was used in 70 cases (51.9%). In 30 cases, these grafts were obtained from local areas such as the acromion, greater tuberosity, or humeral head. In the remaining 40 cases, the graft was obtained from the iliac crest. In 8 cases, tricalcium phosphate granules were used as a substitute for bone graft.<sup>3</sup> **Table IV** reports concurrent shoulder treatments. Rotator cuff repair (125 tears, 56.3%) was the most common concurrent surgical procedure performed, followed by distal clavicle excision (31 cases, 14%) and tenodesis of the long head of the biceps tendon (22 cases, 9.9%).<sup>1,3-5,7,9,12,13,20,24,25,31</sup>

## Excision

No studies directly compared the surgical outcomes of open vs. arthroscopic excision of an os acromiale. Open technique commonly involves separation of the deltoid origin from the os acromiale fragment. Deltoid fibers were noted to be reattached at the end of the procedure to prevent negatively affecting deltoid function. In comparison, several papers cited the benefit of the arthroscopic technique as it minimizes deltoid disruption with preservation

**Table I** Search strategy

Search terms	
os acromiale	
os acromial	
os acromion	
surgery	
treatment	
repair	
excision	
fixation	
No. of studies	
Database	
PubMed	33
Scopus	30
Embase	33
EBSCO	21
Google Scholar	498
Results	
Combined (duplicates removed)	514
After title review	57
After abstract review	38
After full-text review	15

**Table II** Individual study summary

Study authors, yr	No. of subjects	No. of shoulders	Sex	Dominant, nondominant	Mean age, yr	Mean follow-up, mo	Pre-os	Meso-os	Meta-os	Excision	Acromioplasty	K-wire fixation	Screw fixation	Union, nonunion
Warner et al, 1998 <sup>29</sup>	14	15	7 M, 7 F	NR	57	34	1	11	3	3	0	5	7	7, 5
Hertel et al, 1998 <sup>12</sup>	12	15	12 M	11, 4	54	44	0	15	0	0	0	15	0	10, 5
Satterlee, 1999 <sup>25</sup>	6	6	4 M, 2 F	3, 3	48	55	0	6	0	0	0	0	6	6, 0
Ryu et al, 1999 <sup>24</sup>	4	4	3 M, 1 F	2, 2	27	34	0	4	0	0	0	0	4	4, 0
Wright et al, 2000 <sup>31</sup>	12	13	8 M, 4 F	NR	36	29	0	13	0	13	0	0	0	NR
Boehm et al, 2003 <sup>5</sup>	33	33	23 M, 10 F	NR	56	42	3	30	0	6	5	22	0	15, 7
Ozbaydar et al, 2006 <sup>20</sup>	6	6	1 M, 5 F	NR	58.5	29	0	6	0	0	0	2	4	4, 2
Abboud et al, 2006 <sup>1</sup>	19	19	12 M, 7 F	13, 6	53	40	0	19	0	0	11	5	3	8, 0
Pagnani et al, 2006 <sup>21</sup>	9	11	9 M	7, 4	NR	44.6	0	11	0	11	0	0	0	NR
Campbell et al, 2012 <sup>7</sup>	28	31	17 M, 11 F	21, 10	55	41	3	28	0	31	0	0	0	NR
Atoun et al, 2012 <sup>3</sup>	8	8	1 M, 7 F	6, 2	54	22	0	8	0	0	0	0	8	7, 1
Johnston et al, 2013 <sup>13</sup>	6	6	4 M, 2 F	3, 3	53	25	0	6	0	0	6	0	0	NR
Barbier et al, 2013 <sup>4</sup>	10	10	7 M, 3 F	NR	43.3	47.9	0	10	0	0	0	10	0	10, 0
Garcia et al, 2016 <sup>9</sup>	13	13	8 M, 5 F	NR	NR	65.2	0	NR	NR	1	0	0	12	12
Atinga et al, 2018 <sup>2</sup>	31	32	24 M, 7 F	NR	50.2	46.9	NR	NR	NR	0	0	0	32	32, 0

NR, not reported; K-wire, Kirschner wire.

**Table III** Os acromiale and surgical technique breakdown

	n	%
Os acromiale type (when reported)		
Pre-os acromiale	7	4.0
Meso-os acromiale	167	94.4
Meta-os acromiale	3	1.7
Total	177	
Surgical technique		
Excision	65	29.3
Acromioplasty	22	9.9
Fixation	135	60.8
Total	222	
Fixation		
K-wire	59	43.7
Screw	76	56.3
Total	135	

K-wire, Kirschner wire.

of the periosteum and deltoid fascia. There was a total of 65 excisions (20.3%), the majority being meso-os acromiale. Warner et al and Boehm et al had multiple cohorts in their studies in which either open excision or another os acromiale procedure was performed.<sup>5,29</sup> Warner et al reported a good outcome with the open excision of 1 pre-os acromiale that was performed without detaching deltoid fibers. Boehm et al showed a significant improvement in the pain component of the Constant score from 3.3 to 13.4 ( $P = .027$ ) after treatment in the 6 open excisions that they performed (3 pre-os and 3 meso-os acromiales) with deltoid reattachment directly to the bone. All patients had comparable results and overall Constant score (73.2) when compared with their age- and sex-matched cohorts (82%) undergoing acromioplasty or internal fixation.<sup>5</sup>

Wright et al, Pagnani et al, and Campbell et al described patients who underwent arthroscopic excision.<sup>7,21,31</sup> Wright et al performed arthroscopic excision with minimal disruption of deltoid attachment of 13 meso-os acromiales with an overall UCLA score improvement from 17 to 31 and 84.6% patient satisfaction. All patients achieved full anterior deltoid and rotator cuff strength by 6 months postoperatively.<sup>31</sup> Pagnani et al arthroscopically excised 11 meso-os acromiales where the deltoid fascial insertion was preserved and with all patients being able to return to sport 14 weeks post surgery. They all demonstrated no strength deficits in abduction, external rotation, and internal rotation during isokinetic testing when compared with the contralateral side.<sup>21</sup> Campbell et al performed arthroscopic excision with intact periosteal sleeve and deltoid attachment in 31 os acromiales, with 3 pre- and 28 meso-os acromiales. Patient satisfaction was reported at 80.6%, with only 2 patients complaining of increased pain postoperatively. These 2 patients had shown features of glenohumeral arthritis during arthroscopy. A significant improvement ( $P$

**Table IV** Concurrent shoulder treatments

Concurrent surgical treatment	Amount
Rotator cuff repair	125
Distal clavicle excision	31
Long-head biceps tenodesis	22
Rotator cuff debridement	6
Bursal resection	4
SLAP repair	2
Latissimus dorsi transfer	2
Total shoulder arthroplasty	1
AC joint reconstruction	1
Clavicle ORIF	1

AC, acromioclavicular; ORIF, open reduction and internal fixation

< .05) was seen in ASES scores from 33.71 to 80.33, and patients did not show any considerable difference in deltoid power when compared with the contralateral side.<sup>7</sup>

### Acromioplasty

Boehm et al retrospectively compared patients undergoing open acromioplasty, internal fixation, and open excision.<sup>5</sup> In the 5 cases of open acromioplasty of meso-os acromiale, the pain component of the Constant score improved from 4.6 to 12.2 ( $P = .042$ ) postoperatively and 80% patient satisfaction was reported. When compared with age- and sex-matched cohorts undergoing open excision or internal fixation, all patients had comparable results (81%) and overall Constant score (72).<sup>5</sup> Abboud et al performed either arthroscopic (5) or open Neer acromioplasty (6) in 11 patients diagnosed with meso-os acromiale. Patient satisfaction was reported to be 63.6% with improvement in pain ( $P = .0001$ ) and increased functional capacity ( $P = .001$ ) and forward flexion ( $P = .04$ ) but no effect on external rotation. This group was then compared with a cohort of 8 patients who had undergone internal fixation and reported a 37.5% patient satisfaction. Even though patient satisfaction was higher in the acromioplasty group, no statistical comparison was made to determine if there was a significant difference.<sup>1</sup> Johnston et al performed arthroscopic acromioplasty with partial resection in 6 meso-os acromiales with improvements in Penn shoulder score (50.6 to 78.5) and forward flexion (143° to 163°) and decrease in pain (5.6 to 1.3). All parameters showed improvement although this was only significant with the Penn pain score ( $P = .027$ ).<sup>13</sup>

### Internal fixation

Aggregate data showed that internal fixation with screws had a higher rate of radiographic union when compared with internal fixation with Kirschner wires (K-wires) (97.4% vs. 69.5%). Both union and nonunion rates with each internal fixation technique are shown in Table V. The need for hardware removal was greater with K-wires when

compared with screw internal fixation (79.7% vs. 9.2%) as shown in Table VI. Warner et al, Ozbaydar et al, and Abboud et al had multiple cohorts in their studies in which either K-wire or screw internal fixation was performed.<sup>1,20,29</sup> Warner et al performed internal fixation of os acromiale in 12 shoulders with a breakdown of 5 with K-wire with wire tension band and 7 with screw with wire tension band internal fixation technique. Those in the screw with wire tension band internal fixation group had better rates of radiographic union when compared with those in the K-wire with wire tension band group, 85.7% vs. 20%. Patients that achieved radiographic union as a whole had good outcomes, 85.7% of all patients, whereas all those who did not achieve radiographic union had poor outcomes. The patient with a poor outcome was noted to have done poorly because of rotator cuff issues and not because of a failure of the fixation of the os acromiale. Additionally, 2 patients who had initially undergone internal fixation had to have the meso-os acromiale fragment openly excised as a salvage procedure owing to failure of the fixation.<sup>29</sup> Ozbaydar et al reported an overall improvement in UCLA scores (11.8 to 28.2) in 6 patients who underwent internal fixation. There was a 100% union rate in the 4 patients who underwent screw with wire tension band internal fixation vs. a 0% union rate in the 2 who underwent K-wire with wire or nonabsorbable suture tension band internal fixation.<sup>20</sup> Abboud et al reported a 100% union rate in 8 patients who underwent internal fixation for a meso-os acromiale, 5 with K-wire with wire tension band internal fixation, and 3 with screw without tension band internal fixation. Despite the excellent union rate, only 3 of the 8 patients had satisfactory surgical outcomes defined as minimal or no pain, active forward flexion greater than 120°, functional capacity of at least 50% of the contralateral unaffected shoulder, and outcomes subjectively graded as good or excellent.<sup>1</sup>

**Table V** Radiographic union vs. nonunion rates

	n (%)
Overall	
Radiographic union	115 (85.2)
Radiographic nonunion	20 (14.8)
Total attempted internal fixations	135
K-wire technique*	
Radiographic union	41 (69.5)
Radiographic nonunion	18 (30.5)
Total attempted internal fixations	59
Screw technique†	
Radiographic union	74 (97.4)
Radiographic nonunion	2 (2.6)
Total attempted internal fixations	76

K-wire, Kirschner wire.

\* Includes the use of a tension band with wire or nonabsorbable sutures.

† Includes the use of a tension band with wire or nonabsorbable sutures, no tension band, absorbable screws.

**Table VI** Hardware removal rates

Hardware removal	n	% of internal fixations
Overall: includes k-wires, tension band wire, and screws	66	48.9
K-wire technique: includes k-wires and tension band wire; not specified in individual studies	47	79.7
Screw technique: includes screws and tension band wire; not specified in all individual studies	7	9.2

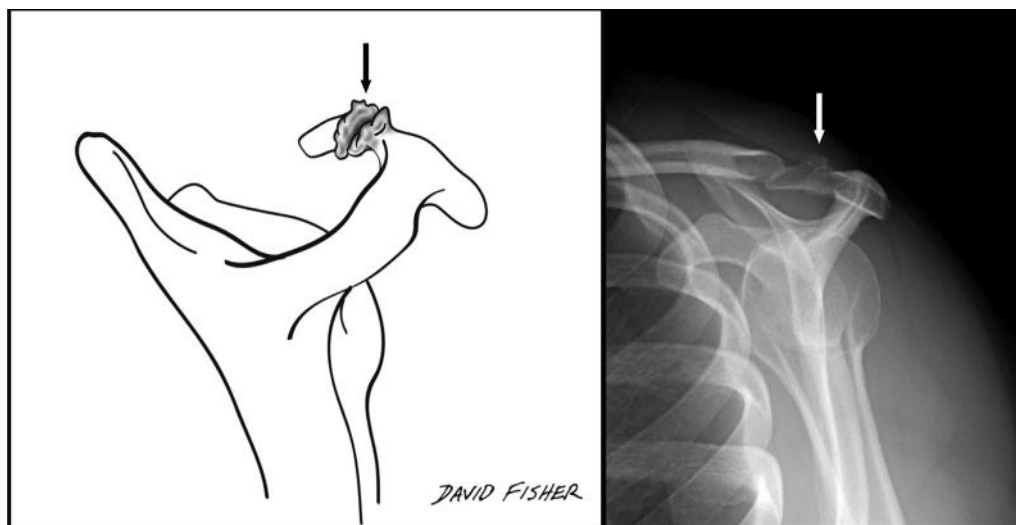
*K-wire*, Kirschner wire.

Hertel et al, Boehm et al, and Barbier et al only performed K-wire internal fixations.<sup>4,5,12</sup> Hertel et al performed K-wire with wire tension band internal fixation in 15 meso-os acromiales with either a deltoid off (devascularized) or a transacromial (vascularized) technique. Patients in the devascularized group achieved radiographic union in 42.9% of the cases, whereas patients in the vascularized group achieved radiographic union in 87.5% of the cases. Those patients who achieved radiographic union had significantly higher Constant scores than those who did not ( $P = .017$ ).<sup>12</sup> In 22 cases of K-wire with wire tension band internal fixation, Boehm et al reported a 68.2% union rate, but there was no difference in Constant scores between those that had achieved union or those that did not. There were also no differences in outcomes when comparing internal fixation vs. open excision or open acromioplasty.<sup>5</sup> Barbier et al reported marked improvements in Constant score from 53.4 to 82.2 but a 100% union and satisfaction rate with internal fixation of 10 meso-os acromiales with K-wires with wire tension band.<sup>4</sup>

In contrast, Satterlee, Ryu et al, Atoun et al, Garcia et al, and Atinga et al only performed screw internal fixations.<sup>2,3,9,24,25</sup> Satterlee reported improvements in ASES scores and excellent results in 6 patients who underwent screw with nonabsorbable suture tension band internal fixation of a meso-os acromiale and achieved radiographic union.<sup>25</sup> Similarly, Ryu et al demonstrated full motion and normal strength with maximum UCLA scores of 35 following screw without tension band internal fixation in 4 patients with meso-os acromiale.<sup>24</sup> Following internal fixation of 8 meso-os acromiales with absorbable screws without tension band, Atoun et al reported a marked improvement in Constant score from 49 to 81 and an 87.5% union rate with 6 full unions and 1 partial union.<sup>3</sup> Garcia et al demonstrated a 100% union rate after screw without tension band internal fixation of 12 os acromiales and an improvement in UCLA scores from 21.5 to 28.9 ( $P = .001$ ). One additional patient had to undergo arthroscopic excision of the os acromiale fragment as a salvage procedure owing to fracture of the os acromiale fragment during screw without tension band internal fixation attempt.<sup>9</sup> Atinga et al reported similar results with a 100% union rate after screw with wire tension band internal fixation of 32 os acromiales.<sup>2</sup>

## Discussion

Os acromiale by its anatomical nature represents a failure of fusion of the acromial apophysis and is inherently unstable. The nonunion site may be symptomatic of pain directly at the site or because of an inflammatory reaction at the nonunion (Fig. 3). The inherent instability of the unfused fragment may lead to a dynamic type of outlet-based impingement syndrome.<sup>14</sup> The medical literature refers to os acromiale as stable or unstable when discussing



**Figure 3** Outlet view of os acromiale. →, osseous changes because of chronic inflammation.

treatment options, but no clear definition has been set as to what stability is with regard to os acromiale. Hasan et al stated that an unstable os acromiale is characterized by a hypermobile anterior acromial fragment with motion through the unfused growth plate.<sup>11</sup> This subjective definition leaves room for interpretation and contributes to the controversy in how to best treat this condition. Because of the ambiguity of definition of stability of the os acromiale, terms of symptomatic vs. asymptomatic os acromiale are more appropriate to guide treatment regimens.

A symptomatic os acromiale may be overlooked as a source of pain especially in shoulders with concomitant pathology including subacromial impingement, acromioclavicular joint arthropathy, and rotator cuff tears. With attempted shoulder movement deltoid fibers pull on the os acromiale fragment leading to dynamic subacromial impingement symptoms or motion across the nonunion site. Currently in the literature, there are 3 surgical techniques that have been described for the treatment of symptomatic os acromiales that have failed conservative management: open or arthroscopic excision, open or arthroscopic acromioplasty, and internal fixation (ie, open reduction and internal fixation). The current medical literature is unclear as to the optimal surgical management for symptomatic os acromiale. The purpose of this systematic review was to summarize the described methods and compare the clinical reported outcomes as well as radiographic results following surgical treatment.

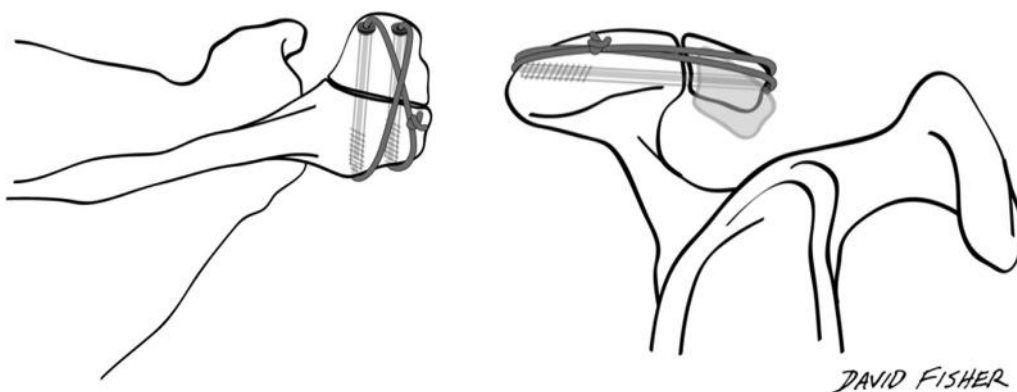
Excision has been reported to be efficacious when the fragment in the os acromiale is small. Studies have reported poor outcomes with larger fragment excision and failure of deltoid origin repair. Neer et al reported on radical acromionectomy with no deltoid origin repair and noticeable weakness and persistent pain that correlated with poor clinical results post-treatment.<sup>18</sup> Bosley reported on patients with total acromionectomy along with deltoid origin repair to the acromion. Patient satisfaction, strength, and function were excellent in 71% of all patients.<sup>6</sup> This review suggests that excision of an os acromiale may produce

favorable clinical outcomes as long as the deltoid origin is preserved or precisely repaired.

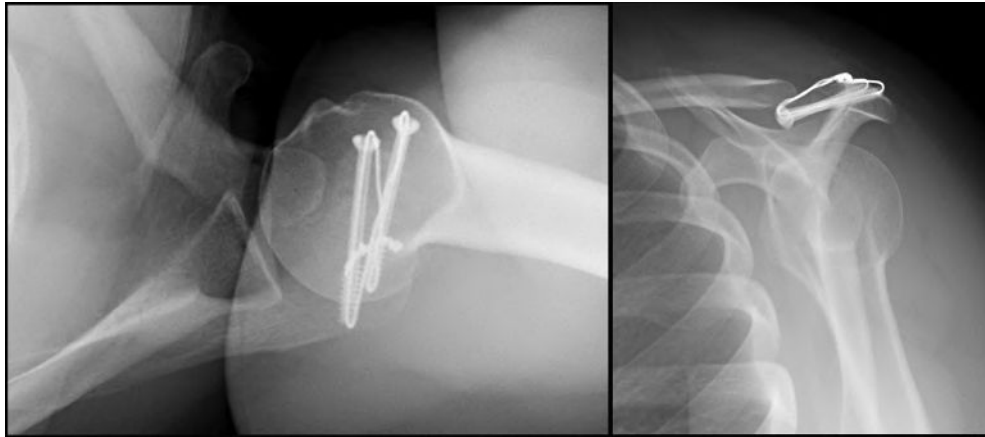
Acromioplasty of a stable os acromiale produces similarly favorable outcomes as excision or internal fixation with age- and sex-matched controls. The purpose of this technique is to reduce the dynamic impingement that occurs on the underside of the acromion with the rotator cuff and subacromial bursa. Acromioplasty, similar to excision, should attempt to preserve the deltoid origin or make sure that it is precisely repaired. Acromioplasty of a symptomatic os acromiale may lead to unfavorable outcomes because of a lack of sufficient reduction in the dynamic impingement mechanism.

Fixation can be used when a patient has a meso-os acromiale and produces favorable clinical outcomes and high rates of radiographic union (Fig. 4). Fixation with screws, when compared with fixation with K-wires, led to higher rates of union as well as improved outcomes and reduced need for hardware removal. The mechanical properties of screws could potentially account for this because screws have a greater thread depth, which helps reduce hardware migration and pullout when compared to K-wires. Owing to the heterogeneity of the data represented, it is difficult to draw conclusions about the importance of adding a tension band construct in addition to screw fixation.

This systematic review has demonstrated that excision of either pre- or meso-os acromiale with a preserved or precisely repaired deltoid origin may produce favorable clinical results, with the achievement of full strength and motion after treatment. Acromioplasty of a meso-os acromiale leads to reduced pain and improved patient satisfaction postoperatively, but there seems to be no statistical difference in outcomes between internal fixation and acromioplasty. For meso os-acromiale, our combined data indicate that internal fixation with screws, when compared to fixation with K-wires, has a higher rate of radiographic union and improved patient outcomes as well as a reduced need for postsurgical hardware removal (Fig. 5).



**Figure 4** Illustration of screw internal fixation with tension band technique.



**Figure 5** Postoperative radiographs of meso-os acromiale after screw internal fixation with tension band technique.

In 2011, Harris et al performed a systematic review of the surgical treatment for symptomatic os acromiale. Their review included 4 studies in which excision was performed as a surgical treatment with 2 studies indicating open technique and 2 studies indicating arthroscopic technique. For acromioplasty, they included 2 studies that reported the use of either open or arthroscopic technique. Lastly, for internal fixation, 7 studies were included in which either K-wire with tension band or screws with and without tension band technique was used. They concluded that surgical management of symptomatic os acromiale might lead to improved outcomes.<sup>10</sup> This review shares many of the same references and finds similar results but does so with a larger study population (78.8%, 211 vs. 118 subjects). For excision, we included 2 additional papers in which arthroscopic technique was reported, and for acromioplasty, we had an additional paper in which arthroscopic technique was also the utilized procedure.<sup>7,9,13</sup> For internal fixation, we included 4 other studies in which 3 reported the use of screws with or without tension band and 1 that indicated the use of K-wires with tension band technique.<sup>2-4,9</sup> One of the additional articles used absorbable screws for internal fixation, which was unique among screw fixation technique studies.<sup>3</sup> Ideally, this broader updated systematic review can help provide some needed clarity in the literature for the optimal surgical treatment of symptomatic os acromiale. A similar undertaking should be performed in the future to determine if current treatment recommendations have changed with surgical or equipment advancements.

The findings in this systematic review are limited in nature by the weakness of each included study. All studies included were retrospectively performed, with only Boehm et al using matched control groups.<sup>5</sup> The sources of selection bias within the review include different numbers of subjects and a limited number of subjects in each treatment group studied. Also, the technique variations within each study, the use of bone graft, and the presence of concurrent shoulder procedures such as rotator cuff repair, distal clavicle excision, and tenodesis of the long head of the biceps tendon all

serve as sources of performance bias. Assessment of outcomes using established tests with measurements by independent observers should be performed to minimize detection bias. Furthermore, heterogeneity of shoulder-specific assessment tools as well lack of a concrete definition of patient satisfaction and os acromiale stability prevents more robust comparison between the studies.

## Conclusions

Operative management of os acromiale leads to decreased symptoms and improvement in clinical outcomes. This can be achieved with open or arthroscopic excision, open or arthroscopic acromioplasty, or internal fixation. Excision is favorable with smaller fragments such as pre-os acromiale and an intact deltoid origin, whereas acromioplasty is useful when there is a stable os acromiale and minimal dynamic impingement on the underside of the acromion. Internal fixation is favorable to fuse larger fragments such as meso- and meta-os acromiale, especially with the use of screws.

## Disclaimer

The authors, their immediate families, and any research foundations with which they are affiliated have not received any financial payments or other benefits from any commercial entity related to the subject of this article.

## References

1. Abboud JA, Silverberg D, Pepe M, Beredjiklian PK, Iannotti JP, Williams GR, et al. Surgical treatment of os acromiale with and without associated rotator cuff tears. *J Shoulder Elbow Surg* 2006;15: 265-70. <https://doi.org/10.1016/j.jse.2005.08.024>



2. Atinga M, Gregor R, Selvaraj KM, Hong TF. Os acromiale open reduction and internal fixation: a review of iliac crest autogenous bone grafting and local bone grafting. *J Shoulder Elbow Surg* 2018;27:1030-6. <https://doi.org/10.1016/j.jse.2017.11.023>
3. Atoun E, van Tongel A, Narvani A, Rath E, Sforza G, Levy O. Arthroscopically assisted internal fixation of the symptomatic unstable os acromiale with absorbable screws. *J Shoulder Elbow Surg* 2012;21:1740-5. <https://doi.org/10.1016/j.jse.2011.12.011>
4. Barbier O, Block D, Dezaly C, Sirveaux F, Mole D. Os acromiale, a cause of shoulder pain, not to be overlooked. *Orthop Traumatol Surg Res* 2013;99:465-72. <https://doi.org/10.1016/j.otsr.2012.10.020>
5. Boehm TD, Matzer M, Brazda D, Gohlke FE. Os acromiale associated with tear of the rotator cuff treated operatively. Review of 33 patients. *J Bone Joint Surg Br* 2003;85:545-9. <https://doi.org/10.1302/0301-620X.85B4.13634>
6. Bosley RC. Total acromionectomy. A twenty-year review. *J Bone Joint Surg Am* 1991;73:961-8.
7. Campbell PT, Nizlan NM, Skirving AP. Arthroscopic excision of os acromiale: effects on deltoid function and strength. *Orthopedics* 2012;35:e1601-5. <https://doi.org/10.3928/01477447-20121023-16>
8. Caspari RB, Thal R. A technique for arthroscopic subacromial decompression. *Arthroscopy* 1992;8:23-30.
9. Garcia J Jr, Gonçalves M, Kozonara M, Pascarelli L, Bongiovanni R. Arthroscopic fixation of os acromiale with cannulated screws. *Acta Shoulder Elbow Surg* 2016;1:44-6.
10. Harris JD, Griesser MJ, Jones GL. Systematic review of the surgical treatment for symptomatic os acromiale. *Int J Shoulder Surg* 2011;5:9-16. <https://doi.org/10.4103/0973-6042.80461>
11. Hasan SA, Shiu B, Jauregui JJ. Symptomatic, unstable os acromiale. *J Am Acad Orthop Surg* 2018;26:789-97. <https://doi.org/10.5435/JAAOS-D-17-00011>
12. Hertel R, Windisch W, Schuster A, Ballmer FT. Transacromial approach to obtain fusion of unstable os acromiale. *J Shoulder Elbow Surg* 1998;7:606-9.
13. Johnston PS, Paxton ES, Gordon V, Kraeutler MJ, Abboud JA, Williams GR. Os acromiale: a review and an introduction of a new surgical technique for management. *Orthop Clin North Am* 2013;44:635-44. <https://doi.org/10.1016/j.ocl.2013.06.015>
14. Kurtz CA, Humble BJ, Rodosky MW, Sekiya JK. Symptomatic os acromiale. *J Am Acad Orthop Surg* 2006;14:12-9.
15. Liberati A, Altman DG, Tetzlaff J, Mulrow C, Gøtzsche PC, Ioannidis JP, et al. The PRISMA statement for reporting systematic reviews and meta-analyses of studies that evaluate health care interventions: explanation and elaboration. *J Clin Epidemiol* 2009;62:e1-34. <https://doi.org/10.1016/j.jclinepi.2009.06.006>
16. Moher D, Liberati A, Tetzlaff J, Altman DG, PRISMA Group. Preferred reporting items for systematic reviews and meta-analyses: the PRISMA statement. *PLoS Med* 2009;6:e1000097. <https://doi.org/10.1371/journal.pmed.1000097>
17. Neer CS. Anterior acromioplasty for the chronic impingement syndrome in the shoulder: a preliminary report. *J Bone Joint Surg Am* 1972;54:41-50.
18. Neer CS, Marberry TA. On the disadvantages of radical acromionectomy. *J Bone Joint Surg Am* 1981;63:416-9.
19. Ortiguera CJ, Buss DD. Surgical management of the symptomatic os acromiale. *J Shoulder Elbow Surg* 2002;11:521-8. <https://doi.org/10.1067/mse.2002.122227>
20. Ozbaydar MU, Keriş I, Altun M, Yalaman O. Results of the surgical treatment for symptomatic mesoacromion. *Acta Orthop Traumatol Turc* 2006;40:123-9. [https://doi.org/10.1162/jocn\\_a\\_00409](https://doi.org/10.1162/jocn_a_00409)
21. Pagnani MJ, Mathis CE, Solman CG. Painful os acromiale (or unfused acromial apophysis) in athletes. *J Shoulder Elbow Surg* 2006;15:432-5. <https://doi.org/10.1016/j.jse.2005.09.019>
22. Park JG, Lee JK, Phelps CT. Os acromiale associated with rotator cuff impingement: MR imaging of the shoulder. *Radiology* 1994;193:255-7.
23. Peckett WRC, Gunther SB, Harper GD, Hughes JS, Sonnabend DH. Internal fixation of symptomatic os acromiale: a series of twenty-six cases. *J Shoulder Elbow Surg* 2004;13:381-5. <https://doi.org/10.1016/j.jse.2004.01.023>
24. Ryu RK, Fan RS, Dunbar WH. The treatment of symptomatic os acromiale. *Orthopedics* 1999;22:325-8.
25. Satterlee CC. Successful osteosynthesis of an unstable mesoacromion in 6 shoulders: a new technique. *J Shoulder Elbow Surg* 1999;8:125-9.
26. Spiegl UJ, Millett PJ, Josten C, Hepp P. Optimal management of symptomatic os acromiale: current perspectives. *Orthop Res Rev* 2018;10:1-7. <https://doi.org/10.2147/ORR.S141480>
27. Spiegl UJA, Smith SD, Todd JN, Wijdicks CA, Millett PJ. Biomechanical evaluation of internal fixation techniques for unstable meso-type os acromiale. *J Shoulder Elbow Surg* 2015;24:520-6. <https://doi.org/10.1016/j.jse.2014.09.040>
28. Stetson WB, McIntyre JA, Mazza GR. Arthroscopic excision of a symptomatic meso-acromiale. *Arthrosc Tech* 2017;6:e189-94. <https://doi.org/10.1016/j.eats.2016.09.021>
29. Warner JJP, Beim GM, Higgins L. The treatment of symptomatic os acromiale. *J Bone Joint Surg Am* 1998;80:1320-6.
30. Winfeld M, Rosenberg ZS, Wang A, Bencardino J. Differentiating os acromiale from normally developing acromial ossification centers using magnetic resonance imaging. *Skeletal Radiol* 2015;44:667-72. <https://doi.org/10.1007/s00256-015-2098-4>
31. Wright RW, Heller MA, Quick DC, Buss DD. Arthroscopic decompression for impingement syndrome secondary to an unstable os acromiale. *Arthroscopy* 2000;16:595-9.
32. Yammine K. The prevalence of os acromiale: a systematic review and meta-analysis. *Clin Anat* 2014;27:610-21. <https://doi.org/10.1002/ca.22343>
33. Zember JS, Rosenberg ZS, Kwong S, Kothary SP, Bedoya MA. Normal skeletal maturation and imaging pitfalls in the pediatric shoulder. *Radiographics* 2015;35:1108-22. <https://doi.org/10.1148/rg.2015140254>