



Ultrasound assessment after a subscapularis-sparing approach to total shoulder arthroplasty

Jun Kit He, MD^a, Samuel Huntley, MD^a, Alexandra Arguello, MD^a,
David Adkison, MD^a, Matthew Larrison, MD^a, Gerald McGwin, PhD^a,
Amit Momaya, MD^a, Brent Ponce, MD^b, Eugene Brabston, MD^{a,*}

^aDepartment of Orthopaedic Surgery, University of Alabama at Birmingham, Birmingham, AL, USA

^bThe Hughston Clinic, Columbus, GA, USA

Background: Although anatomic total shoulder arthroplasty (ATSA) has favorable outcomes, nearly all techniques involve subscapularis tendon release for shoulder joint access. Such takedown of the subscapularis may be associated with decreased function, instability, and pain. Subscapularis-sparing approaches have the theoretical benefits of improved function, decreased failure of the tendon reattachment site, and early range of motion and rehabilitation. The primary purpose of this study was to use ultrasound to assess the postoperative integrity of the subscapularis tendon and surrounding soft tissues after ATSA with a subscapularis-sparing technique through an extensile anterosuperior skin incision. Our hypothesis was that this subscapularis-sparing approach would have low rates of subscapularis disruption.

Methods: A consecutive cohort of patients who underwent subscapularis-sparing ATSA between 2014 and 2017 were included. Ultrasound was used to evaluate the rotator cuff tendons and deltoid postoperatively, and these were classified as intact, disrupted, or unable to be adequately visualized. Clinical outcome scores, range of motion, and strength measurements were also collected at 1–3 years postoperatively.

Results: Thirty-seven subscapularis tendons and 40 supraspinatus and infraspinatus muscles were adequately visualized and included for analysis. Of the subscapularis muscles, 32 (86%) were intact; 38 of the visualized supraspinatus muscles (95%) and 39 of the infraspinatus muscles (98%) were intact. No dehiscence or loss of integrity of the deltoid was noted. Clinical comparison between patients with disrupted subscapularis muscles and patients without such disruption demonstrated no difference in clinical outcome scores and postoperative range of motion but showed less strength in forward flexion, abduction, and external rotation.

Conclusions: The rate of subscapularis disruption using a subscapularis-sparing approach for ATSA was low (14%), but the potential for tendon disruption was not eradicated. Favorable clinical outcomes support this surgical approach as a potential technique for ATSA.

Level of evidence: Level IV; Case Series; Treatment Study

© 2022 Journal of Shoulder and Elbow Surgery Board of Trustees. All rights reserved.

Keywords: Shoulder arthroplasty; approach; subscapularis sparing; rotator interval; ultrasound; patient-reported outcomes

The University of Alabama at Birmingham Institutional Review Board approved this study (study no. 170519005)

*Reprint requests: Eugene Brabston, MD, Department of Orthopaedic Surgery, University of Alabama at Birmingham, 1313 13th St S, Birmingham, AL 35233, USA.

E-mail address: ebrabston@uabmc.edu (E. Brabston).

Anatomic total shoulder arthroplasty (ATSA) is the third most common joint replacement operation and reliably relieves pain, improves function, and achieves high rates of patient satisfaction.^{10,24} Nearly all surgical techniques involve release of the subscapularis tendon to access the shoulder joint. This is involved regardless of whether a tenotomy, lesser tuberosity osteotomy, or peel of the tendon

off the lesser tuberosity is performed.^{15,30} All of these techniques put the subscapularis at risk, and damage to the tendon is associated with decreased function, instability, and pain.^{2,6,15,19,20,22} Reported rates of subscapularis tears following ATSA vary widely, ranging from 3% to 47%.^{2,3,5,13-15,19,22} To help protect the repaired subscapularis tendon, rehabilitation may be modified. Delayed motion may facilitate healing but result in stiffness whereas early range of motion may impair tendon healing.^{4,5} In an attempt to better preserve subscapularis integrity during ATSA, subscapularis-sparing techniques have been described.^{9,17,31}

Only 1 prior study has assessed the subscapularis-sparing technique radiographically,²⁹ and none have assessed the other rotator cuff tendons and deltoid. The purpose of this study was to use ultrasound to assess the postoperative integrity of the subscapularis tendon and surrounding soft tissues after ATSA with a subscapularis-sparing technique through an extensile anterosuperior skin incision. Our hypothesis was that this subscapularis-sparing approach would have low rates of subscapularis disruption.

Materials and methods

In this case series, we recruited consecutive patients who underwent subscapularis-sparing ATSA performed by a single surgeon (D.A.) between 2014 and 2017. Patients with at least 1 year of follow-up were included. Patients who underwent revision surgery, had significant glenoid deformity, or underwent reverse total shoulder arthroplasty (TSA) were excluded.

Ultrasound evaluation

Ultrasound examination was completed by a trained operator, using a previously described technique, between 1 and 3 years postoperatively.⁶ The bicipital groove was identified, and the biceps tendon was visualized in the short axis below the groove for orientation. Static images of the subscapularis tendon were taken in both the long axis and the short axis. The subscapularis was assessed with both passive and active dynamic views for integrity. The supraspinatus, infraspinatus, and deltoid were evaluated, and any disruption vs. attenuation was noted. To include the soft tissue envelope, the depth ranged from 3.5 to 4.5 cm.⁶

The muscles were classified as intact, disrupted, or unable to be adequately visualized. Evaluation was based on continuity from the lesser tuberosity tendon insertion to the muscular belly that was inferior and medial to the coracoid process. Intact tendons were further subcategorized as being full thickness or attenuated. A classification of “attenuated” involved a hypochoic defect and focal decrease > 50% in the thickness of the tendon or thickness < 6 mm. A fully disrupted tendon had retraction from the bone, medial retraction of the muscle belly, and a gap in the tendon substance. Tendons were classified as “unable to be adequately visualized” if the images did not display normal anatomic landmarks.²⁷ The ultrasound assessment was recorded and then reviewed by a fellowship-trained musculoskeletal radiologist (M.L.).

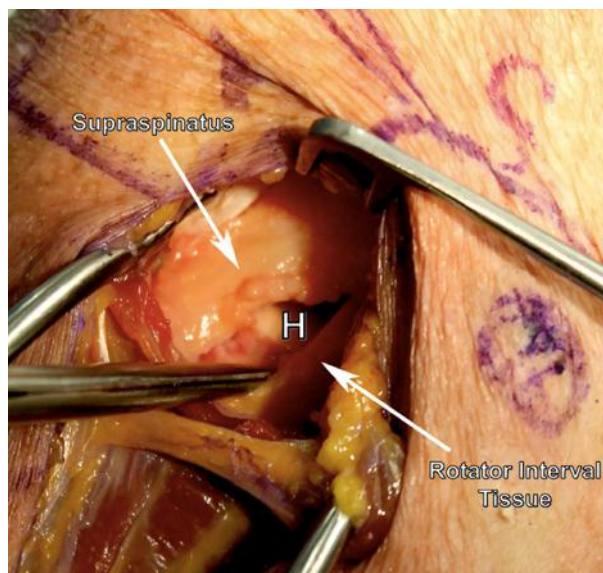


Figure 1 Trapdoor incision posterior to biceps tendon and medial to glenoid tubercle. From the upper subscapularis, an incision in the rotator interval tissue is made laterally. Superior to the humeral head (H), the leading edge of the supraspinatus is appreciated.

Clinical evaluation and functional outcome evaluation

The American Shoulder and Elbow Surgeons (ASES) score,¹ 12-Item Short Form Survey (SF-12) score,⁷ Simple Shoulder Test (SST) score,¹ Single Assessment Numeric Evaluation (SANE) score,³³ short version of the Disabilities of the Arm, Shoulder and Hand questionnaire (QuickDASH) score,^{11,16} and visual analog scale (VAS) pain score²¹ were collected.

Range-of-motion and strength measurements

For range of motion and strength, forward flexion, abduction, external rotation, and internal rotation of both the affected arm and unaffected arm were tested postoperatively. External rotation was tested with the patient's arm at his or her side and in 90° of abduction. Internal rotation was tested by determining the highest spinous level the patient could reach with his or her thumb and with the arm in 90° of abduction. Range of motion was measured with a goniometer. Strength was measured using a Mark-10 Force Gauge Series 3 dynamometer (Copiague, NY, USA).

Statistical analysis

Data are presented as means and standard deviations. The Kruskal-Wallis test was used to compare preoperative and postoperative outcomes, as well as range of motion and strength of the operative and unaffected shoulders. SAS software (SAS Institute, Cary, NC, USA) was used for all analyses and $P < .05$ was considered significant.

Table I Patient demographic characteristics

Characteristic	Data (N = 46)
Age, yr	
Mean ± SD	61.0 ± 8.1
Range	37.1-78.1
Sex: F/M	21/25
Operative shoulder: R/L	25/21
Follow-up duration, mo	
Mean ± SD	24.1 ± 8.1
Range	12.1-40.8

SD, standard deviation; F, female; M, male; R, right; L, left.

Operative technique: rotator interval approach

The surgical technique followed was identical to that of Ransom et al.²⁷ An anterosuperior straight “saber” incision was made starting 1 cm medial to the anterolateral acromion margin in the anterior-inferior direction and extending approximately 10 cm. Dissection was carried medially to the acromioclavicular joint. The raphe between the anterior and middle deltoid was opened, and subdeltoid adhesions were released. A trapdoor flap was created in the rotator interval with the shoulder externally rotated (Fig. 1). The long head of the biceps was released. Through the trapdoor, humeral head osteotomy and removal of humeral osteophytes were performed, along with preparation of the glenoid. Because the approach was superior to the subscapularis, the axillary nerve was not within the surgical field and was not handled. Retractors were placed inferiorly to protect the axillary pouch, as well as anteriorly to protect the subscapularis and axillary nerve.

Results

Forty-six patients were included in the study. The average patient age was 61 years (range, 37-78 years), and the mean follow-up duration was 2 years (range, 12.1-40.8 months) (Table I). Thirty-seven subscapularis and 40 supraspinatus and infraspinatus muscles were adequately visualized and included. In total, 32 of the subscapularis muscles (86%), 38 of the supraspinatus muscles (95%), and 39 of the infraspinatus muscles (98%) were intact, whereas 19 subscapularis muscles (65%), 16 supraspinatus muscles (40%),

and 15 infraspinatus muscles (38%) were attenuated. No appreciable attenuation or dehiscence of the deltoid was noted in any of the patients (Table II).

Regarding the clinical outcomes of the 46 patients who underwent ATSA surgery with the subscapularis-sparing technique, both the VAS score (7.8 ± 2.0 to 0.9 ± 1.5 , $P < .001$) and SANE score (29.8 ± 22.1 to 88.2 ± 14.5 , $P < .001$) improved. The postoperative ASES score was 89.9 ± 14.2 ; SF-12 physical score, 41.6 ± 7.6 ; SF-12 mental score, 47.8 ± 5.9 ; SST score, 11.2 ± 2.0 ; and QuickDASH score, 7.8 ± 13.2 (Table III). When range of motion and strength were compared between the affected and unaffected arms postoperatively, abduction strength showed a significant difference (4.7 ± 2.1 kilogram-force vs. 6.0 ± 2.4 kilogram-force, $P = .005$) (Table IV). Comparison of patients with ($n = 5$, 14%) and without ($n = 32$, 86%) disrupted subscapularis muscles showed no difference in pain scores, clinical outcome scores, and postoperative range of motion (Table V). Patients with disrupted subscapularis muscles had less strength in forward flexion ($P = .037$), abduction ($P = .016$), and external rotation with the arm abducted ($P = .016$) compared with patients with intact subscapularis muscles but showed no difference in internal rotation (Table VI).

Review of preoperative magnetic resonance imaging (MRI) showed 1 independent case each of preoperative supraspinatus, infraspinatus, and deltoid deficiency. The 1 patient in whom postoperative supraspinatus insufficiency developed had lower-than-average postoperative strength and range of motion except internal rotation. Despite these limitations, this patient had better-than-average postoperative VAS, SANE, ASES, and QuickDASH scores and an average SST score.

Discussion

In this case series investigating soft tissue outcomes following subscapularis-sparing ATSA via an extensile anterosuperior skin incision, we demonstrated subscapularis preservation in 86% of patients on ultrasound evaluation. Patients with intact subscapularis tendons had greater forward flexion, abduction, and external rotation

Table II Postoperative integrity of rotator cuff and deltoid muscles assessed

	Subscapularis muscle, n (%)	Supraspinatus muscle, n (%)	Infraspinatus muscle, n (%)	Deltoid dehiscence, n (%)
Intact				
Fully	13 (35)	22 (56)	24 (62)	45 (100)
Attenuated	19 (51)	16 (41)	15 (38)	0
Disrupted	5 (14)	1 (3)	0	0
Unable to be adequately visualized	9	6	6	
Disrupted preoperatively	0	1	1	1

Percentages were calculated excluding the muscles that were unable to be visualized or were disrupted preoperatively.

Table III Clinical outcome scores of all participants

Outcome score	Mean \pm SD (N = 46)
VAS	
Preoperative	7.8 \pm 2.0
Postoperative	0.9 \pm 1.5
Improvement	6.9 \pm 2.7 ($P < .001$)
SANE	
Preoperative	29.8 \pm 22.1
Postoperative	88.2 \pm 14.5
Improvement	58.3 \pm 31.2 ($P < .001$)
Postoperative ASES	
Pain score	44.7 \pm 9.1
Functional score	45.2 \pm 7.3
Total score	89.9 \pm 14.2
Postoperative SF-12	
Physical score	41.6 \pm 7.6
Mental score	47.8 \pm 5.9
Postoperative SST	11.2 \pm 2.0 (93%)
Postoperative QuickDASH	7.8 \pm 13.2

SD, standard deviation; VAS, visual analog scale; SANE, Single Assessment Numeric Evaluation; ASES, American Shoulder and Elbow Surgeons; SF-12, 12-Item Short Form Survey; SST, Simple Shoulder Test; QuickDASH, short version of Disabilities of the Arm, Shoulder and Hand questionnaire.

For Postoperative SST, 93% represents the score percentage (11.2/12).

strength than those with disrupted tendons. However, there were no differences in range of motion, internal rotation strength, or patient-reported outcome measures between the groups. Reported theoretical benefits of a subscapularis-sparing approach include improved function, a decreased failure rate of the tendon reattachment site, and no requirement for protection in a sling, thus allowing early active range of motion and postoperative rehabilitation.^{9,17,26,31} With our favorable clinical outcomes and subscapularis tendon disruption rate being on the lower end of previously reported rates among ATSA patients (3%-47%), we believe that this method is a safe and reliable alternative to traditional approaches.^{2,3,5,13-15,19,22}

Ultrasound analysis in this series revealed disruption of the rotator cuff muscles including 5 of 37 subscapularis muscles (14%) and 1 supraspinatus tear (3%). These data fall on the lower end of reported rates of disruption, but the risk is not eradicated as hoped.^{2,3,5,13-15,19,22} The number of disruptions may be lower than reported as ultrasound differentiation between a tear and the surgical soft tissue trapdoor was difficult. Secondary traction deltoid dehiscence was a concern as the muscle is split, but no new cases of disruption were identified. Although the anterosuperior approach avoids gross detachment of the subscapularis, the disruptions of the subscapularis and supraspinatus may be due to extensive retraction for visualization. This concern was voiced by Simovitch et al³¹ and Ding et al,⁹ although they also did not appreciate any clinical impact. The only other prior imaging assessment of the subscapularis

following a subscapularis-sparing technique for hemiarthroplasty was performed by Savoie et al²⁹ using MRI in 19 shoulders and ultrasound in 24 shoulders, demonstrating intact subscapularis tendons without atrophy or fatty infiltration. Despite the technique involving a partial subscapularis takedown of the inferior subscapularis, 2- and 5-year follow-up revealed intact subscapularis tendons, demonstrating long-term integrity.²⁹

Ultrasound's fast, inexpensive, and noninvasive nature makes it an ideal tool for assessing tissue integrity in a research setting. Even though it is operator dependent, it has been shown to be accurate in evaluating rotator cuff integrity, even after TSA.^{2,3} MRI is not ideal for postoperative imaging as extensive metal artifacts obscure image quality. Computed tomography arthrography is also not an ideal imaging modality because it is an invasive procedure that exposes the patient to dye and additional radiation. Other studies have investigated the role of ultrasound in examining the subscapularis following ATSA. O'Malley et al²⁵ used blinded ultrasound and successfully determined subscapularis integrity in 86.7% of patients (26 of 30) at 6 months postoperatively. The results at earlier follow-up intervals were less successful owing to postoperative edema obscuring the ultrasound findings. Armstrong et al² similarly used ultrasound to assess the subscapularis at least 8 months after TSA. They visualized the subscapularis in all 30 patients and diagnosed a tear in 13% of patients.²

The traditional deltopectoral approaches with takedown of the subscapularis with either a tenotomy, osteotomy, or peel place the muscle and tendon at risk.¹⁸ Beyond the risk of postoperative disruption of the subscapularis from these techniques, takedown and repair of the subscapularis in ATSA have been associated with increased postoperative fatty infiltration of the muscle and weakness in internal rotation.^{12,15} A systematic review by Louie et al²⁰ demonstrated a greater degree of subscapularis tearing and/or attenuation in patients undergoing tenotomy (5.2%) than in those undergoing lesser tuberosity osteotomy (2.2%).²⁰ Takedown and repair of the subscapularis appear to permit the highest risk of disruption, with 14%-47% of cases having full-thickness tears.^{2,15} Although not zero, the subscapularis disruption rate of 14% in our study was on the lower end of the reported range for other various subscapularis takedown approaches.

The surgical approach used in this study is based on a technique described by Debeyre et al⁸ adapted for reverse TSA.²³ The surgeon (D.A.) modified this into an anterolateral approach through the rotator interval. The proposed benefits of this surgical approach include avoidance of tenotomy of the subscapularis tendon, improved access to the glenoid, improved soft tissue management, and visualization of the entire rotator cuff. Enhancing improved in-line visualization of the glenoid is especially important with excessive glenoid retroversion. Our incision is made from the anterolateral acromion in the anterior-inferior direction,

Table IV Postoperative range of motion and strength of all participants (N = 46)

	Range of motion, mean ± SD, °	Strength, mean ± SD, kgf
Forward flexion		
Affected side	152.0 ± 24.0	6.1 ± 2.9
Unaffected side	154.0 ± 30.0	6.7 ± 2.7
Difference	-2.0 ± 37.0 (<i>P</i> = .743)	-0.6 ± 3.0 (<i>P</i> = .175)
Abduction		
Affected side	136.0 ± 27.0	4.7 ± 2.1
Unaffected side	146.0 ± 33.0	6.0 ± 2.4
Difference	-10.0 ± 36.0 (<i>P</i> = .091)	-1.3 ± 2.3 (<i>P</i> = .005)
External rotation: arm at side		
Affected side	55.0 ± 14.0	5.6 ± 2.3
Unaffected side	59.0 ± 16.0	5.8 ± 2.4
Difference	-4.0 ± 17.0 (<i>P</i> = .094)	-0.1 ± 2.3 (<i>P</i> = .696)
External rotation: arm abducted		
Affected side	70.0 ± 18.0	5.5 ± 2.4
Unaffected side	78.0 ± 22.0	6.3 ± 3.0
Difference	8.0 ± 28.0 (<i>P</i> = .051)	-0.8 ± 2.9 (<i>P</i> = .058)
Internal rotation: arm abducted		
Affected side	54.0 ± 16.0	8.3 ± 3.2
Unaffected side	56.0 ± 27.0	8.7 ± 4.2
Difference	-2.0 ± 25.0 (<i>P</i> = .604)	-0.4 ± 2.8 (<i>P</i> = .339)
Internal rotation: spinous process		
Affected side	T10 ± 3	
Unaffected side	T9 ± 4	
Difference	-1 (<i>P</i> = .246)	

SD, standard deviation; kgf, kilogram-force.

an opening that can be extended into the deltopectoral or cephalic vein region and distally if needed, allowing increased visualization and glenohumeral exposure. Humeral head sizing disks have been developed to address the

issue of component under-sizing. Rotation of implants for final implantation continues to be difficult, although a curved, short stem helps. Regarding osteophytes, this approach allows the surgeon to “drop in” for resection and the majority were removed with initial humeral head osteotomy with a curette or secondary vertical calcar region cut. There is a risk of anterior deltoid weakening.²³ However, in this ultrasound assessment, we demonstrated favorable rates of surrounding soft tissue integrity and clinical outcomes.

Various subscapularis-sparing approaches have been developed in an attempt to avoid damaging the subscapularis tendon. Lafosse et al¹⁸ (2009) described a technique through the rotator interval in 22 patients. Early outcomes were favorable, with all patients showing intact belly-press test results, but there was difficulty in visualizing and accessing the anterior shoulder with a high rate of radiographic evidence of improper humeral head osteotomy (35%), residual inferior humeral head osteophytes (47%), and head implant under-sizing (29%).¹⁸ Simovitch et al³² (2015) introduced a deltopectoral approach with an inferior subscapularis muscular window performed in a series of 3 patients with favorable clinical outcomes demonstrating intact internal rotation. In a series of 46 patients treated by use of a window, Ding et al⁹ noted that poor visualization problems persisted as retained osteophytes and humeral head diameter mismatch remained when

Table V Comparison of clinical outcome scores in patients with intact vs. disrupted subscapularis muscles (n = 37)

Postoperative clinical outcome score	Intact	Disrupted	<i>P</i> value
VAS	0.9	0.6	.979
Change in VAS	7.0	7.6	.667
SANE	86.7	96.6	.204
Change in SANE	55.4	72.2	.285
ASES			
Pain	44.5	46	.957
Functional	45.7	47.3	.855
Total	90.2	93.3	.682
SF-12			
Physical	45.7	49.4	.420
Mental	53.2	52.3	.841
SST	11.2	12	.299
QuickDASH	7.9	7.7	.593

VAS, visual analog scale; SANE, Single Assessment Numeric Evaluation; ASES, American Shoulder and Elbow Surgeons; SF-12, 12-Item Short Form Survey; SST, Simple Shoulder Test; QuickDASH, short version of Disabilities of the Arm, Shoulder and Hand questionnaire.

Table VI Comparison of ROM and strength in patients with intact vs. disrupted subscapularis muscles (n = 37)

	Intact	Disrupted	P value
Forward flexion			
ROM, °	153.0	154.0	.641
Strength, kgf	6.0	3.6*	.037
Forward flexion difference			
ROM, °	4.0	-11.0	.155
Strength, kgf	-0.4	-1.3	.399
Abduction			
ROM, °	137.0	142.0	.876
Strength, kgf	4.7	2.6*	.016
Abduction difference			
ROM, °	-3.0	-9.0	.450
Strength, kgf	-1.0	-1.8	.296
External rotation: arm at side			
ROM, °	57.0	48.0	.491
Strength, kgf	5.5	3.9	.142
External rotation difference: arm at side			
ROM, °	-2.0	-13.0	.213
Strength, kgf	0.04	-0.6	.756
External rotation: arm abducted			
ROM, °	72.0	68.0	.477
Strength, kgf	5.7*	3.2*	.016
External rotation difference: arm abducted			
ROM, °	-4.0	-18.0	.162
Strength, kgf	-0.4	-1.6	.230
Internal rotation: arm abducted			
ROM, °	51.0	63.0	.149
Strength, kgf	7.8	6.9	.689
Internal rotation difference: arm abducted			
ROM, °	-1.0	12.0	.505
Strength, kgf	-0.2	0.9	.307
Internal rotation: spinous process			
ROM, °	T9	T12	.136
Difference	-0.03	-1.8	.468

ROM, range of motion; kgf, kilogram-force.

* Indicates $P < .05$.

compared with a traditional deltopectoral approach.³⁰ In 2018, Routman and Savoie²⁸ reported a technique that improved visualization of the humeral head but involved a partial tenotomy of the inferior portion of the subscapularis. Savoie et al²⁹ noted intact lift-off, bear-hug, and belly-press test findings in their series of 50 patients. In 2019, Kwon and Zuckerman¹⁷ described a procedure that also involved splitting the inferior portion of the subscapularis. However, they voiced the concern of limited exposure leading to difficulty in reproducing the native anatomy of the shoulder, resecting osteophytes, and releasing the joint capsule, as well as the procedure being technically challenging, especially in patients with anterior soft tissue bulk or medially eroded joints.¹⁷ More recently, the subscapularis-sparing technique of Ransom et al²⁷ demonstrated comparable radiographic positioning of implants compared with a traditional takedown and repair of the subscapularis tendon.

Functional outcome scores following shoulder arthroplasty with a subscapularis-sparing approach have been promising. Lafosse et al,¹⁸ Simovitch et al,³¹ Savoie et al,²⁹ and Kwon and Zuckerman¹⁷ all reported improvements in pain. Kwon and Zuckerman reported no differences in pain and function between patients undergoing the subscapularis-sparing approach and those undergoing standard ATSA. Our patients had comparable postoperative pain scores to these previous studies. The mean ASES score was greater than that described by Savoie et al and Kwon and Zuckerman, and the SST score was greater than that reported in the patients of Lafosse et al. The SF-12 scores (both physical and mental scores) were lower than reported in the patients reported on by Savoie et al. Our series showed lower abduction strength compared with the nonoperative shoulder. Patients with disrupted subscapularis tendons had less strength in forward flexion,

abduction, and external rotation but no differences in range of motion. We hypothesize that the reduced external rotation strength may be a result of inhibition due to pain. Rather than true external rotation weakness, this action may lead to anterior subluxation of the implant, potential apprehension, and pain inhibition. Although no specific tests for the subscapularis were conducted, these shoulders were functional albeit having some detriments resulting from the operation. These outcomes do not confer superiority over other subscapularis-sparing techniques but support that the described technique is a viable option with comparable outcomes.

This study is not without limitations. As this is a case series, no patients undergoing standard TSA or other subscapularis-sparing approaches were included for comparison. Furthermore, patients who had undergone revision surgery were excluded. The small sample size was partially because of a number of cases in which the muscles were unable to be adequately visualized for assessment. Given the nature of ultrasound imaging, we were unable to assess for additional changes in tissue quality, including fatty infiltration. For patient-reported outcomes, although VAS scores were obtained preoperatively and postoperatively, the ASES, SF-12, SST, and QuickDASH scores were only assessed postoperatively. Moreover, we did not assess subscapularis-specific physical examination maneuvers, including the lift-off or belly-press test. Although this information would have been beneficial, we chose not to include these tests as the primary focus of this work was on subscapularis tissue integrity, rather than clinical outcomes. Finally, we did not evaluate component positioning. However, previous work by Ransom et al²⁷ demonstrated that prosthesis positioning does not significantly differ between subscapularis-sparing techniques and traditional deltopectoral approaches.

Conclusion

A modified subscapularis-sparing technique for TSA results in low rates of subscapularis and deltoid injury based on ultrasound examination. Despite concerns for potential iatrogenic injury, patients showed substantial clinical improvement, which suggests that this approach may provide the benefits of subscapularis preservation, increased visualization of the superior glenoid, improved soft tissue management, and accelerated rehabilitation.

Disclaimers

Funding: No funding was disclosed by the authors.
Conflicts of interest: Brent Ponce is a paid consultant for Stryker, Smith & Nephew, and ODi and receives

royalties from Stryker. All the other authors, their immediate families, and any research foundations with which they are affiliated have not received any financial payments or other benefits from any commercial entity related to the subject of this article.

References

1. Angst F, Schwyzer H-K, Aeschlimann A, Simmen BR, Goldhahn J. Measures of adult shoulder function: Disabilities of the Arm, Shoulder, and Hand Questionnaire (DASH) and its short version (QuickDASH), Shoulder Pain and Disability Index (SPADI), American Shoulder and Elbow Surgeons (ASES) Society standardized shoulder. *Arthritis Care Res (Hoboken)* 2011;63:S174-88. <https://doi.org/10.1002/acr.20630>
2. Armstrong A, Lashgari C, Teeffey S, Menendez J, Yamaguchi K, Galatz LM. Ultrasound evaluation and clinical correlation of subscapularis repair after total shoulder arthroplasty. *J Shoulder Elbow Surg* 2006;15:541-8. <https://doi.org/10.1016/j.jse.2005.09.013>
3. Armstrong AD, Southam JD, Horne AH, Hollenbeak CS, Flemming DJ, Kothari MJ. Subscapularis function after total shoulder arthroplasty: electromyography, ultrasound, and clinical correlation. *J Shoulder Elbow Surg* 2016;25:1674-80. <https://doi.org/10.1016/j.jse.2016.02.018>
4. Boardman ND III, Cofield RH, Bengtson KA, Little R, Jones MC, Rowland CM. Rehabilitation after total shoulder arthroplasty. *J Arthroplasty* 2001;16:483-6.
5. Böhm E, Scheibel M, Lädermann A. Subscapularis insufficiency: what's all the fuss about? *J Shoulder Elb Arthroplast* 2018;2:2471549218792370. <https://doi.org/10.1177/2471549218792370>
6. Buckley T, Miller R, Nicandri G, Lewis R, Voloshin I. Analysis of subscapularis integrity and function after lesser tuberosity osteotomy versus subscapularis tenotomy in total shoulder arthroplasty using ultrasound and validated clinical outcome measures. *J Shoulder Elbow Surg* 2014;23:1309-17. <https://doi.org/10.1016/j.jse.2013.12.009>
7. Busija L, Pausenberger E, Haines TP, Haymes S, Buchbinder R, Osborne RH. Adult measures of general health and health-related quality of life: Medical Outcomes Study Short Form 36-Item (SF-36) and Short Form 12-Item (SF-12) Health Surveys, Nottingham Health Profile (NHP), Sickness Impact Profile (SIP), Medical Outcomes Study Short Form 6D (SF-6D), Health Utilities Index Mark 3 (HUI3), Quality of Well-Being Scale (QWB), and Assessment of Quality of Life (AQoL). *Arthritis Care Res (Hoboken)* 2011;63:S383-412. <https://doi.org/10.1002/acr.20541>
8. Debeyre J, Patie D, Elmelik E. Repair of ruptures of the rotator cuff of the shoulder. *J Bone Joint Surg Br* 1965;47:36-42.
9. Ding DY, Mahure SA, Akuoko JA, Zuckerman JD, Kwon YW. Total shoulder arthroplasty using a subscapularis-sparing approach: a radiographic analysis. *J Shoulder Elbow Surg* 2015;24:831-7. <https://doi.org/10.1016/j.jse.2015.03.009>
10. Fisher ES, Bell J-E, Tomek IM, Esty AR, Goodman DC, Bronner KK. Trends and regional variation in hip, knee, and shoulder replacement. A Dartmouth Atlas Surgery Report. 2010. <http://hdl.handle.net/10244/1014>
11. Franchignoni F, Vercelli S, Giordano A, Sartorio F, Bravini E, Ferriero G. Minimal clinically important difference of the Disabilities of the Arm, Shoulder and Hand outcome measure (DASH) and its shortened version (QuickDASH). *J Orthop Sports Phys Ther* 2014;44:30-9. <https://doi.org/10.2519/jospt.2014.4893>
12. Gerber C, Yian EH, Pfirrmann CAW, Zumstein MA, Werner CML. Subscapularis muscle function and structure after total shoulder replacement with lesser tuberosity osteotomy and repair. *J Bone Joint Surg Am* 2005;87:1739-45. <https://doi.org/10.2106/JBJS.D.02788>

13. Gobezie R, Denard PJ, Shishani Y, Romeo AA, Lederman E. Healing and functional outcome of a subscapularis peel repair with a stem-based repair after total shoulder arthroplasty. *J Shoulder Elbow Surg* 2017;26:1603-8. <https://doi.org/10.1016/j.jse.2017.02.013>
14. Ives EP, Nazarian LN, Parker L, Garrigues GE, Williams GR. Subscapularis tendon tears: a common sonographic finding in symptomatic postarthroplasty shoulders. *J Clin Ultrasound* 2013;41:129-33. <https://doi.org/10.1002/jcu.21980>
15. Jackson JD, Cil A, Smith J, Steinmann SP. Integrity and function of the subscapularis after total shoulder arthroplasty. *J Shoulder Elbow Surg* 2010;19:1085-90. <https://doi.org/10.1016/j.jse.2010.04.001>
16. Kennedy CA, Beaton DE, Solway S, McConnell S, Bombardier C. In: *Disabilities of the Arm, Shoulder and Hand (DASH). The DASH and Quick DASH outcome measure user's manual*. 3rd ed. Toronto: Institute for Work & Health; 2011.
17. Kwon YW, Zuckerman JD. Subscapularis-sparing total shoulder arthroplasty: a prospective, double-blinded, randomized clinical trial. *Orthopedics* 2019;42:e61-7. <https://doi.org/10.3928/01477447-20181109-02>
18. Lafosse L, Schnaser E, Haag M, Gobezie R. Primary total shoulder arthroplasty performed entirely thru the rotator interval: technique and minimum two-year outcomes. *J Shoulder Elbow Surg* 2009;18:864-73. <https://doi.org/10.1016/j.jse.2009.03.017>
19. Liem D, Kleeschulte K, Dedy N, Schulte TL, Steinbeck J, Marquardt B. Subscapularis function after transosseous repair in shoulder arthroplasty: transosseous subscapularis repair in shoulder arthroplasty. *J Shoulder Elbow Surg* 2012;21:1322-7. <https://doi.org/10.1016/j.jse.2011.09.022>
20. Louie PK, Levy DM, Bach BR Jr, Nicholson GP, Romeo AA. Subscapularis tenotomy versus lesser tuberosity osteotomy for total shoulder arthroplasty: a systematic review. *Am J Orthop (Belle Mead NJ)* 2017;46:E131-8.
21. McCormack HM, Horne DJ, Sheather S. Clinical applications of visual analogue scales: a critical review. *Psychol Med* 1988;18:1007-19.
22. Miller BS, Joseph TA, Noonan TJ, Horan MP, Hawkins RJ. Rupture of the subscapularis tendon after shoulder arthroplasty: diagnosis, treatment, and outcome. *J Shoulder Elbow Surg* 2005;14:492-6. <https://doi.org/10.1016/j.jse.2005.02.013>
23. Molé D, Wein F, Dézaly C, Valenti P, Sirveaux F. Surgical technique: the anterosuperior approach for reverse shoulder arthroplasty. *Clin Orthop Relat Res* 2011;469:2461-8. <https://doi.org/10.1007/s11999-011-1861-7>
24. Norris TR, Iannotti JP. Functional outcome after shoulder arthroplasty for primary osteoarthritis: a multicenter study. *J Shoulder Elbow Surg* 2002;11:130-5. <https://doi.org/10.1067/MSE.2002.121146>
25. O'Malley MP, Kia C, Dukas AG, Cote M, Stock H, Savoy L, et al. Blinded ultrasound examination of the subscapularis following anatomic shoulder arthroplasty. *J Shoulder Elb Arthroplast* 2019;3:2471549219832442. <https://doi.org/10.1177/2471549219832442>
26. Poignard A, Bouhou M, Homma Y, Hernigou P. Enlarged transacromial superior approach with reverse shoulder arthroplasty for fractures. *Orthop Rev (Pavia)* 2011;3:e2. <https://doi.org/10.4081/or.2011.e2>
27. Ransom EF, Adkison DP, Woods DP, Pinto MC, He JK, Worthen JV, et al. Subscapularis sparing total shoulder arthroplasty through a superolateral approach: a radiographic study. *J Shoulder Elbow Surg* 2020;29:814-20. <https://doi.org/10.1016/j.jse.2019.08.009>
28. Routman HD, Savoie FHB. Subscapularis-sparing approaches to total shoulder arthroplasty: ready for prime time? *Clin Sports Med* 2018;37:559-68. <https://doi.org/10.1016/j.csm.2018.05.006>
29. Savoie FH III, Charles R, Casselton J, O'Brien MJ, Hurt JA III. The subscapularis-sparing approach in humeral head replacement. *J Shoulder Elbow Surg* 2015;24:606-12. <https://doi.org/10.1016/j.jse.2014.07.020>
30. Shields E, Ho A, Wiater JM. Management of the subscapularis tendon during total shoulder arthroplasty. *J Shoulder Elbow Surg* 2017;26:723-31. <https://doi.org/10.1016/j.jse.2016.11.006>
31. Simovitch R, Fullick R, Kwon Y, Zuckerman JD. Use of the subscapularis preserving technique in anatomic total shoulder arthroplasty. *Bull Hosp Jt Dis* 2013;71:94-100.
32. Simovitch R, Fullick R, Zuckerman JD. Subscapularis preserving technique in anatomic total shoulder arthroplasty. The superior and inferior approach. *Bull Hosp Jt Dis* 2015;73:S154-60.
33. Williams GN, Gangel TJ, Arciero RA, Uhorchak JM, Taylor DC. Comparison of the Single Assessment Numeric Evaluation method and two shoulder rating scales. Outcomes measures after shoulder surgery. *Am J Sports Med* 1999;27:214-21.