

# Distal clavicle autograft for anterior-inferior glenoid augmentation: A comparative cadaveric anatomic study

Parke W Hudson, Martim C Pinto, Eugene W Brabston, Matthew C Hess, Brent M Cone , Johnathan F Williams, William S Brooks, Amit M Momaya and Brent A Ponce 

## Abstract

**Introduction:** The aim of this study was to anatomically compare distal clavicle and coracoid autografts and their potential to augment anterior-inferior glenoid bone loss.

**Methods:** Ten millimeters of distal clavicle and 20 mm of coracoid were harvested bilaterally from 32 cadavers. Length, weight, and height were measured and surface area and density were calculated. For each graft, ipsilateral measurements were compared and the ability to restore corresponding glenoid bone loss was calculated.

**Results:** Distal clavicle grafts were larger than coracoid grafts with respect to length (22.3 mm versus 17.7 mm;  $p < 0.001$ ), height (12.49 mm versus 9.65 mm;  $p < 0.001$ ), mass (2.72 g versus 2.45 g;  $p = 0.0437$ ), and volume ( $2.36 \text{ cm}^3$  versus  $1.96 \text{ cm}^3$ ;  $p = 0.002$ ). Coracoid grafts had larger widths (14.56 mm versus 10.52 mm;  $p < 0.001$ ) and greater density ( $1.24 \text{ g/cm}^3$  versus  $1.18 \text{ g/cm}^3$ ;  $p < 0.001$ ). Distal clavicle surface area was greater on both the articular ( $2.93 \text{ cm}^2$  versus  $1.5 \text{ cm}^2$ ;  $p < 0.001$ ) and superior surfaces ( $2.76 \text{ cm}^2$  versus  $1.5 \text{ cm}^2$ ;  $p < 0.001$ ) when compared to lateral coracoid surface area.

**Discussion:** Distal clavicle grafts were larger and restored larger bony defects but had greater variability and lower density than coracoid grafts. Clinical studies are needed to compare these graft options.

## Keywords

distal clavicle, coracoid, glenoid, bone loss, autograft, cadaveric

Date received: 5th December 2018; revised: 12th July 2019; accepted: 14th July 2019

## Introduction

Shoulder instability associated with anterior-inferior glenoid bone loss is challenging to treat. A reported 78–91% of recurrent anterior shoulder dislocations involve some degree of glenoid bone loss.<sup>1–3</sup> Smaller lesions can be treated without bony augmentation, but traditionally when the size of a lesion exceeds a threshold of 21% of glenoid width, arthroscopic soft tissue repair alone may not be effective.<sup>4,5</sup> More recent literature has examined concomitant variables such as humeral head defects and introduced the concept of glenoid tracking,<sup>6,7</sup> but the consensus treatment for substantial glenoid bone loss remains augmentation of the glenoid contact area.<sup>8,9</sup>

The most common glenoid augmentation techniques involve free transfer allogenic<sup>10</sup> or autogenic<sup>11</sup> bone

graft, such as a coracoid transfer.<sup>12</sup> However, coracoid transfer procedures are technically difficult and have been associated with significant complication rates.<sup>13,14</sup> Delaney et al.<sup>15</sup> reported that neuromonitoring identified 76.5% of patients had nerve alert episodes during a Latarjet procedure with 20.6% having clinically detectable postoperative nerve deficits. However, systematic reviews have showed much lower rates of neurovascular compromise<sup>12,16,17</sup> and found many nerve injuries to

Department of Orthopaedic Surgery, University of Alabama at Birmingham, Birmingham, USA

### Corresponding author:

Brent A Ponce, Department of Orthopaedic Surgery, University of Alabama at Birmingham, HGLD 209, 1720 2nd Ave S, Birmingham, AL 35294, USA.  
Email: bponce@uabmc.edu

be temporary.<sup>17</sup> Additionally, biomechanical studies have suggested Latarjet procedures do not improve inferior stability as much as previously thought and may increase the risk of superior translation.<sup>18,19</sup>

Given both realized and potential complications, alternative graft options for glenoid bone augmentation have been proposed, such as femoral head allograft,<sup>10</sup> distal tibia allograft,<sup>20</sup> iliac crest autograft,<sup>11</sup> and distal clavicle autograft.<sup>21</sup> Favorable clinical outcomes have been reported with each of the former three graft choices.<sup>10,11,20</sup> The distal clavicle autograft has the advantage of utilizing the articular cartilage of the acromioclavicular (AC) joint, although it is thinner than that of the glenoid.<sup>22</sup> The harvest is more accessible than the coracoid and results in minimal patient morbidity.<sup>23</sup> A recent biomechanical analysis showed distal clavicle bone graft to be comparable to the coracoid with regard to contact area and mean and peak pressure with resection 1 cm medial to the distal end sufficient to reconstruct a 25% vertical glenoid defect.<sup>24</sup> Despite potential advantages of the distal clavicle as a graft option for anterior glenoid reconstruction, there have been no anatomic studies comparing the distal clavicle to the coracoid.

The primary purpose of this cadaveric anatomic study was to quantify the dimensions, surface area, volume, mass, and density of the distal clavicle in comparison to the coracoid process. The secondary purpose was to determine the percentage of articular glenoid contact area that could be reconstructed by either graft. We hypothesized that the distal clavicle would have comparable measurements to those of the coracoid and would reconstruct a similar percentage of the articular surface area.

## Methods

The distal clavicle, coracoid, and glenoid were bilaterally harvested from 32 cadavers (64 shoulders). Age, gender, and the dimensions of the distal clavicle and coracoid were recorded. One specimen was excluded for prior surgery, one for prior fracture, and three for significant osteolysis/arthritis causing irregular shaping of the distal clavicle and limiting the validity of our measurements on these specimens, resulting in 59 specimens included in the analysis.

### Specimen harvest and preparation

The distal clavicle was harvested with an oscillating saw (Stryker Corporation, Kalamazoo, MI) and was cut 10 mm medial and parallel with the AC joint.<sup>13</sup> The coracoid was similarly harvested with a length of 20 mm along the coracoid axis, in accordance with the upper end of documented lengths in Cowling et al.<sup>12</sup> The inferior surface was flattened to be placed flush

with the glenoid as in a Latarjet procedure.<sup>25</sup> The bones were cleared of soft tissue and cartilage, and the glenoid cleared of the labrum, to allow bony dimensions to be accurately measured.

## Measurements


The distal clavicle and coracoid grafts were measured with a Vernier caliper (Fowler High Precision, Auburndale, MA) at three places in the anterior to posterior (length) plane, medial to lateral (width) plane, and superior to inferior (height) plane. Caliper measurements were taken to the nearest 0.5 mm. These measurements were averaged to obtain a mean value for each plane. Distal clavicle and coracoid length, width, and height measurements were taken at three evenly spaced locations along each axis (Figures 1 and 2). The glenoid width was measured from the anterior bony edge of the glenoid rim to the posterior edge at the widest part of the glenoid as described by Churchill et al.<sup>26</sup> (Figure 3).

The area of the glenoid was calculated in cm<sup>2</sup>, by  $(\text{glenoid width}/2)^2 \times \pi$ , using glenoid width as the diameter of a perfect circle.<sup>4</sup> For the distal clavicle, two surface areas, the articular (lateral) and superior, were measured due to its proposed versatility.<sup>21</sup> These surface area measurements were performed electronically using ImageJ (National Institute of Health, Bethesda, MD) (Figure 4). The proposed articular surface area was measured to estimate each graft's ability to restore the surface area of a deficient glenoid. A "percent of glenoid area" was calculated for each potential graft articular surface:  $(\text{surface area of potential graft/glenoid surface area}) \times 100$ . The "percent of glenoid width" was calculated by  $(\text{distal clavicle width OR coracoid height/glenoid width}) \times 100$ .

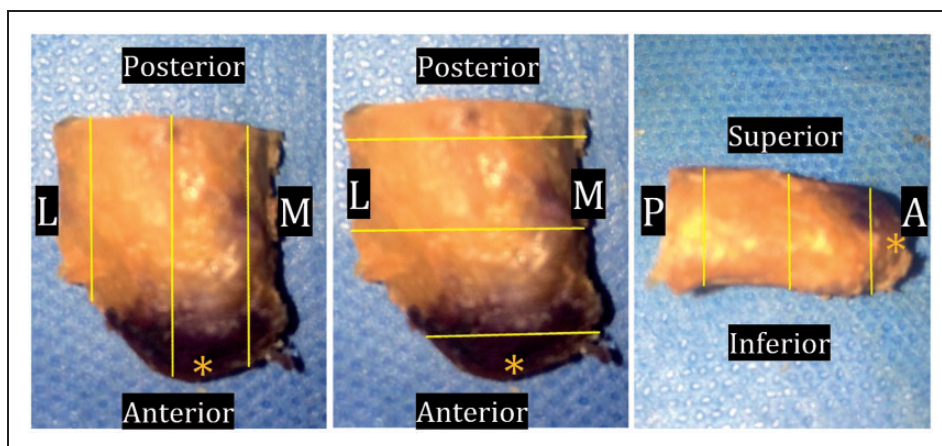
Mass was obtained by weighing each specimen to the nearest 0.01 g. Volume in cm<sup>3</sup> was calculated assuming each bone was an elliptical cylinder. For the distal clavicle, the equation was  $(L/2 \times H/2 \times \pi) \times W$ , and for the coracoid it was  $(W/2 \times H/2 \times \pi) \times L$ , with L, H, and W representing average length, height, and width, respectively. Density in g/cm<sup>3</sup> was calculated by dividing mass by volume.

## Statistical analysis

The means and ranges of the cadaveric samples were calculated for length, width, height, mass, volume, and density. Mean and ranges of surface area and the percent of glenoid area were calculated for the lateral coracoid, articular clavicle, and superior clavicle as well as percent of glenoid width for distal clavicle and coracoid height. Measurements and calculations were compared between the distal clavicle and coracoid grafts using a t test to



**Figure 1.** Distal clavicle measurements: length (left side), width from superior view (middle), and height from lateral view (right side). Yellow lines demonstrate the distances measured. For all dimensions, each of the two lateral measurements was made 2 mm from the edge of the bone while the middle measurement was made midway between the two lateral lines. The three measurements were averaged to calculate each dimension. A: anterior; L: lateral; M: medial; P: posterior; \*Tip of the distal clavicle.



**Figure 2.** Coracoid measurements: length (left side), width from superior view (middle), and height from lateral view (right side). Yellow lines demonstrate the distances measured. For all dimensions, each of the two lateral measurements was made 2 mm from the edge of the bone while the middle measurement was made midway between the two lateral lines. The three measurements were averaged to calculate each dimension. A: anterior; L: lateral; M: medial; P: posterior; \*Tip of the coracoid.

assess for statistical significance. Pearson correlation was performed to assess the relationship between distal clavicle articular area, distal clavicle superior area, coracoid lateral area, and glenoid area as well as distal clavicle height, coracoid height, and glenoid width.

Simulated glenoid width bone loss percentages of 20, 25, 30, 35, and 40% were then calculated. Each of these values was compared to the height of the distal clavicle and height of the coracoid from the corresponding shoulder. The percent of specimens in which a given dimension of graft was greater than a given percentage of glenoid width in the same specimen is shown in Figure 5. Next, simulated glenoid surface area bone loss percentages of 20, 25, 30, 35, and 40% were then calculated.<sup>4,8,27</sup> Each of these values was compared to

the surface area of articular clavicle, superior clavicle, and lateral coracoid from the corresponding shoulder. The percent of specimens in which a given dimension of graft was greater than a given percentage of glenoid surface area in the same specimen is shown in Figure 5.

All statistical analysis was performed in Microsoft Excel (Redmond, WA). The level of significance for all tests was set at a p-value of 0.05.

## Results

### Demographics

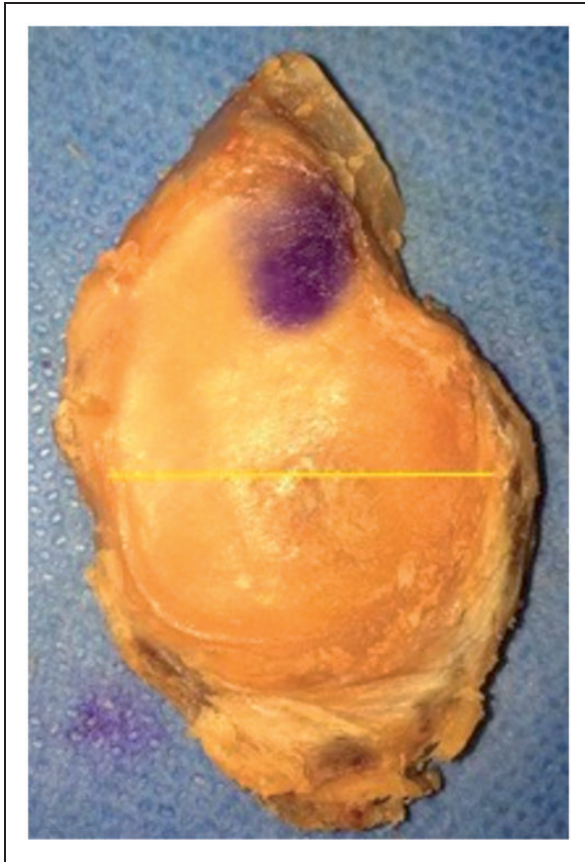
The average age and weight of the cadaveric specimens was 79.2 years (range 54–95) and 61.2 kg



(range 37.2–97.5 kg), respectively. Overall, 41% (13/32) were male. Forty-seven percent (28/59) of specimens analyzed were from the right side.

### *Distal clavicle versus coracoid measurements*

The average height, length, articular area, and graft volume of the distal clavicle were larger than the respective coracoid measurements ( $p < 0.0001$ ).




**Figure 3.** Glenoid measurement. The yellow line indicates the maximum anterior to posterior width of the glenoid that was measured.

The coracoid had larger width and density compared to the distal clavicle ( $p < 0.001$ ). Measurements are found in Table 1.

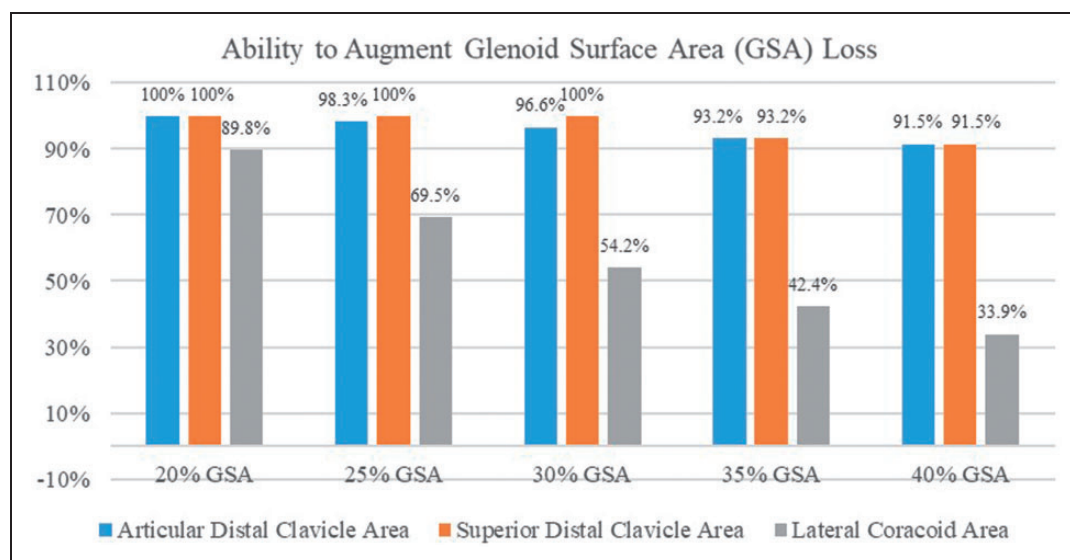
### *Glenoid measurements and sufficiency of bone loss augmentation*

The average glenoid width was 24.1 mm (range 17–32 mm). On average, 20% of glenoid width equated to 4.8 mm, 25% to 6.0 mm, 30% to 7.2 mm, 35% to 8.4 mm, and 40% to 9.6 mm. The average height of the articular surface of the clavicle (to account for extension of width with grafting) was 52.2% of glenoid width (range 33.3–75.0%) and the average height of the coracoid was 40.6% of glenoid width (range 21–101.5%) (Table 1). Clavicle width was not considered, as this measure was solely dependent on osteotomy site. Clavicle height was more strongly correlated ( $r = 0.480$ ) with glenoid width than coracoid height ( $r = 0.145$ ). Using each native specimen for each individual cadaver, distal clavicle height was regularly larger than higher percentages of glenoid width when compared to coracoid height (Figure 6).

Glenoid area was calculated to be  $4.64 \text{ cm}^2$  (range  $2.27\text{--}8.04 \text{ cm}^2$ ). Thus, on average, 20% glenoid articular area equated to  $0.93 \text{ cm}^2$ , 25% to  $1.16 \text{ cm}^2$ , 30% to  $1.39 \text{ cm}^2$ , 35% to  $1.62 \text{ cm}^2$ , and 40% to  $1.86 \text{ cm}^2$ . The average surface area of the articular distal clavicle was 64.5% of its corresponding glenoid articular area (range 35.6–105.7%), while the average surface area of the superior distal clavicle was 61.7% of the glenoid (range 31.0–107.5%). The average surface area of the lateral coracoid was 34.0% of glenoid surface area (range 15.0–52.4%) (Table 1). Articular distal clavicle area was most strongly correlated with glenoid area ( $r = 0.468$ ), followed by lateral coracoid area ( $r = 0.299$ ), and superior distal clavicle area ( $r = 0.239$ ). Using each native specimen for each individual cadaver, both distal clavicle articular and superior surface area were regularly larger than higher percentages of glenoid surface when compared to coracoid lateral coracoid surface area (Figure 5).



**Figure 4.** Surface area measurements. ImageJ software calculation for surface area of the lateral coracoid (left side), articular distal clavicle (middle), and superior distal clavicle (right side).



**Figure 5.** Frequency distribution showing sufficiency of glenoid augmentation at varying percentages of glenoid surface area bone loss.

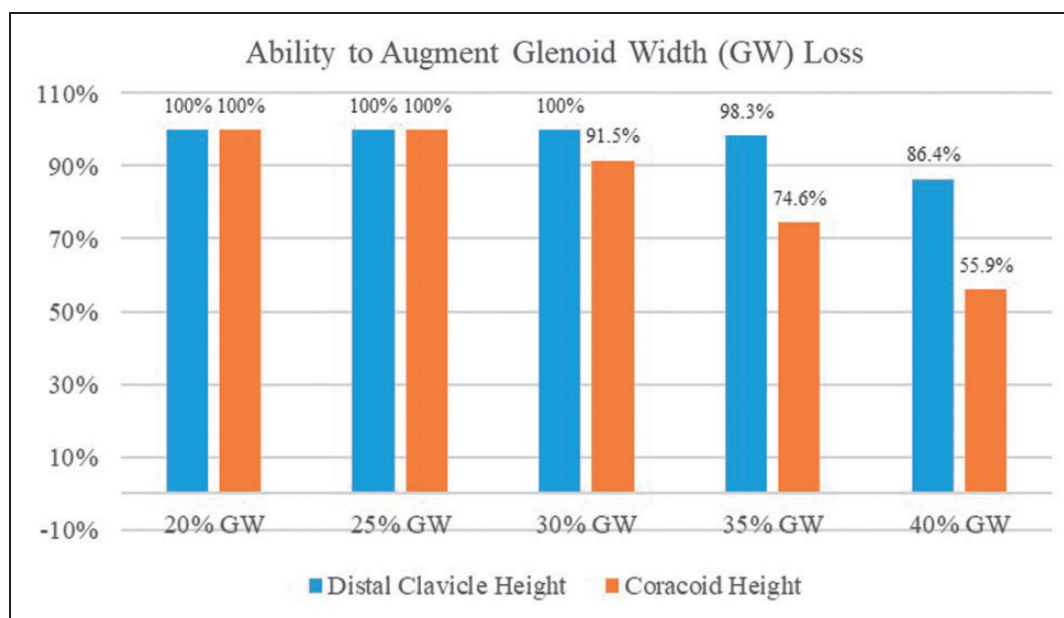
**Table 1.** Measurements of distal clavicle and coracoid grafts.

	Distal clavicle measurements	Range (min, max)	Coracoid measurements	Range (min, max)	Difference	p-value
Height (mm)	12.5	7, 18	9.7	5.8, 23.3	2.8	<0.001
Length (mm)	22.3	12.8, 31.5	17.7	13.3, 21	4.6	<0.001
Width (mm)	10.5	7.8, 14.5	14.6	10.8, 20	-4.0	<0.001
Articular or lateral surface area (cm <sup>2</sup> )	2.93	1.29, 4.82	1.5	0.68, 2.16	1.43	<0.001
Articular or lateral % of glenoid surface area	64.5%	35.6%, 105.7%	34%	15.0%, 52.4%	30.5%	<0.001
Superior distal clavicle surface area (cm <sup>2</sup> )	2.76	1.54, 4.32	—	—	1.26	<0.001
Superior distal clavicle % of glenoid surface area	61.7%	31.0%, 107.5%	—	—	27.3%	<0.001
Height %width of glenoid	52.2%	33.3%, 75.0%	40.6%	25%, 101.5%	41.7%	<0.001
Mass (g)	2.72	0.96, 4.62	2.45	1.53, 4.00	0.27	0.044
Volume (cm <sup>3</sup> )	2.36	0.65, 4.64	1.96	1.03, 3.27	0.4	0.002
Density (g/cm <sup>3</sup> )	1.18	0.69, 1.62	1.24	0.83, 1.84	-0.06	<0.001

## Discussion

Glenoid bone deficiency is a difficult and commonly encountered condition when treating shoulder instability. Multiple glenoid augmentation grafts have been proposed, and this cadaveric study is the first to

quantify and compare the dimensions of the distal clavicle to the coracoid as potential glenoid bone grafts. Although no clinical assessment was performed in this study, we provide evidence for the potential efficacy of distal clavicle autograft for glenoid bone loss and this technique has been used in a small pilot cohort by



**Figure 6.** Frequency distribution showing sufficiency of glenoid augmentation at varying percentages of glenoid width bone loss.

Tokish et al.<sup>21</sup> although their work is devoid of quantified clinical outcomes.

Overall, the distal clavicle yielded significantly more graft than the coracoid did. This was an unexpected finding as the measured cut from the distal clavicle was 1 cm compared to 2 cm for the coracoid process. However, the osteotomy-independent linear measurements (length and height), mass, and calculated volume were greater in distal clavicle grafts. Additionally, both the surface area of the articular distal clavicle and the superior distal clavicle were nearly twice that of the lateral coracoid (2.9 and 2.8 cm<sup>2</sup> versus 1.5 cm<sup>2</sup>), allowing the grafted distal clavicle to potentially fill larger glenoid defects—particularly defects over 25% of the glenoid. The specimens were modified to measure the lateral coracoid as the primary articular surface in lieu of the inferior surface as described in the congruent arc modification,<sup>28</sup> as biomechanical studies have found the congruent arc to be less stable.<sup>29,30</sup> While the distal clavicle articular cartilage surface can provide a cartilage covered graft option to restore glenoid bone loss, the preparation of the inferior or superior surface would slightly decrease its augmentation ability.

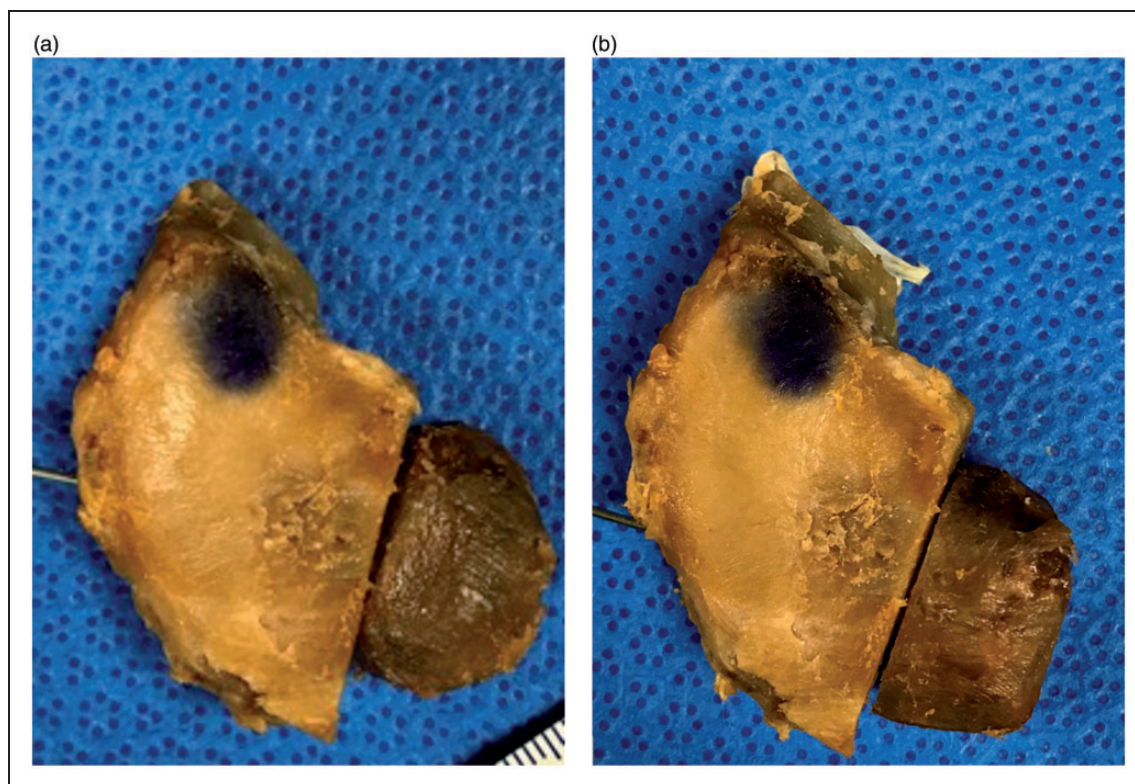
The coracoid grafts exhibited greater density than distal clavicle grafts. This is likely related to larger amount of cortical bone in the coracoid, compared to the distal clavicle, from the constant stress of the conjoined tendon.<sup>31</sup> Despite increasing use of bony glenoid augmentation in recent years,<sup>32</sup> the incidence of graft resorption in coracoid grafts remains high,<sup>33</sup> theoretically increasing the risk of chondral injury to the

humerus. It is unknown how the differing density of these two grafts, in addition to the potential for the coracoid to remain vascularized, may influence the likelihood of graft reabsorption.

The distal clavicle possesses advantages as a potential graft due to its anatomical position, surface composition, and versatility. Resection of the distal clavicle is a relatively safe procedure commonly performed for persistent AC joint pain,<sup>34,35</sup> while coracoid transfer procedures have been associated with nerve complications in 8–21% of patients.<sup>13,14</sup> If the noncoracoid graft is able to be placed arthroscopically through the rotator interval, there may be even less potential for subscapularis injury or transient neuropraxia.<sup>36</sup> Harris et al.<sup>23</sup> suggested resection should be performed less than 1.5 cm (15 mm) medially from the AC joint in order to avoid coracoclavicular ligament injury and resultant instability. Petersen et al.<sup>24</sup> followed this guidance by performing distal clavicle resection 1 cm (10 mm) medial to the AC joint in their study, while Tokish et al.<sup>21</sup> stayed even closer (6–8 mm) to the AC joint. The distal clavicle also has an articular cartilage surface that is comparable to, though slightly thinner than, the glenoid,<sup>22</sup> allowing it to restore a more native glenoid articular surface than coracoid transfers or other bony autografts,<sup>11</sup> without the financial cost or antigenicity risk associated with osteochondral allografts.<sup>20,37</sup> Patients that typically require bony augmentation to the glenoid are younger and would more likely have preservation of the distal clavicle articular surface.

Due to the attachment of the conjoined tendon, coracoid transfer techniques have limited versatility of the





**Figure 7.** Model of distal clavicle graft augmentation of glenoid curvature. (a) articular (lateral) surface augmenting the glenoid contact area and (b) superior or inferior cortex augmenting the glenoid contact area.

graft as the reported techniques either have the inferior surface (i.e. Young et al.<sup>25</sup> and Lafosse et al.<sup>38</sup>) or the medial surface (i.e. DeBeer et al.<sup>39</sup>) flush with the glenoid. Nonetheless, from our measurements, the glenoid joint surface augmentation would be greater with the DeBeer and Burkhart technique as the average width of the coracoid was 14.6 mm and height 9.7 mm. The theoretical advantage of using distal clavicle is that there are multiple other orientations that the surgeon may choose regarding the alignment of the free autograft in relation to the glenoid face (Figure 7(a) and (b)). Potential advantages of the distal clavicle need to be considered in light of the reported success of both Latarjet and Bristow coracoid transfer procedures which utilize the sling effect of the conjoint tendon to produce superior biomechanical stability compared to bony augmentation alone by decreasing translation of the humeral head with abduction and internal/external rotation as well as decreasing dislocations of the humeral head with abduction and external rotation.<sup>40,41</sup>

In larger defects more sizable amounts of bone may be required. As shown by Warner et al.<sup>11</sup> who utilized autogenous tricortical iliac crest bone graft to restore defects over 50% of glenoid width with good clinical results. We found average distal clavicle height to be more than 50% of glenoid width, suggesting the distal

clavicle may be a viable option for augmentation of larger defects. Finally, fixation differs between coracoid transfer procedure and distal clavicle glenoid augmentation. Traditionally, two screws have been used to fix the coracoid graft to the glenoid.<sup>12</sup> Although we did not measure the area of the inferior or superior coracoid graft specifically, our study found an average length of 17.7 mm and width of 14.6 mm, which would yield an inferior/superior area of 2.58 cm<sup>2</sup> (assuming a rectangle). Prior studies have shown that screws in the Latarjet procedure are bordered by about 4 mm of bone on each side.<sup>42</sup> In contrast, Tokish et al.<sup>21</sup> described the placement of only one screw for fixation when using the distal clavicle for glenoid augmentation, thus potentially exposing the graft to rotational instability. If the distal clavicle graft is placed with its cut medial edge flush with the glenoid, so that its superior surface augments the glenoid curvature, the average length (22.3 mm) and height (12.5 mm) make dimensions favorable for two screw fixation. However, if the graft is placed so that the osteochondral, articular surface of the distal clavicle augments the glenoid curvature, the limited average width of the graft (10.5 mm) would limit the potential for two screw fixation. Additionally, the increased variability of the distal clavicle could further complicate fixation. For

these reasons, further investigation into specialized fixation constructs of the graft may be beneficial.

### Limitations

This study is not without limitations. The mean age of the cadavers in this study is much older than those who typically undergo shoulder stabilization procedures. This may have affected measurements of the distal clavicle due to an increased prevalence of osteoarthritis which commonly affects the AC joint.<sup>43</sup> For example, the distal clavicle grafts had greater variability than coracoid grafts with regard to all measurements. It is unknown whether this variability would decrease with younger specimens. Nonetheless, we attempted to exclude all patients who showed advanced degenerative changes at the AC joint. Additionally, the irregular shape of the bones likely had some effect on measurement, and while we tried to control for this by taking three measurements in each plane, subtle imperfections likely occurred. For example, a previous anatomic study concluded that the coracoid available for transfer had a mean 23.9mm length, 15.3mm width, and 11.6mm height.<sup>44</sup> Our coracoid measurements of 17.8mm length, 14.6mm height, and 10mm width were less, likely representing differences in graft preparation and cadaver specimens. The irregularity likely also impacted the precision of our calculation of volume, in which we assumed each bone to be an elliptical cylinder. Finally, this study is a cadaveric anatomical study, and further studies need to be completed in the clinical setting to evaluate the distal clavicle as a graft option for anterior glenoid bone loss in the setting of shoulder instability.

### Conclusion

In this cadaveric study, the distal clavicle, as a potential glenoid autograft, has a greater height, length, articular area, volume, mass, and variability (range in measurements) than the coracoid process. While no clinical testing was performed with the distal clavicle, this cadaveric study demonstrates the theoretical ability to restore glenoid bone loss. Potential advantages of distal clavicle autograft including ease of accessibility, autogenic osteochondral articular surface, and versatility need to be weighed against the successful clinical results with coracoid autograft options when selecting a potential graft choice to augment glenoid deficiency in the surgical treatment of shoulder instability.

### Acknowledgment

This manuscript has been accepted for a podium presentation on ASES Annual Meeting 2017.

### Declaration of Conflicting Interests

The author(s) declared no potential conflicts of interest with respect to the research, authorship, and/or publication of this article.

### Ethical approval

Not applicable for this article.

### Funding


The author(s) received no financial support for the research, authorship, and/or publication of this article.

### Author contributions

All authors were instrumental in the collection of data, data analysis, and writing and editing of the manuscript. Specifically, Hudson and Ponce were the project leaders, overseeing all aspects of the study. Pinto, Hess, Cone, and Brooks were instrumental in obtaining and measuring cadaveric specimens as well as writing and editing of the manuscript. Brabston, Williams, and Momaya played crucial roles in overseeing data analysis as well as writing and editing of the manuscript.

### ORCID iDs

Brent M Cone  <https://orcid.org/0000-0002-2528-7074>

Brent A Ponce  <https://orcid.org/0000-0002-8925-540X>

### References

1. Sugaya H, Moriishi J, Dohi M, et al. Glenoid rim morphology in recurrent anterior glenohumeral instability. *J Bone Joint Surg Am* 2003; 85-A: 878–884.
2. Edwards TB, Boulahia A and Walch G. Radiographic analysis of bone defects in chronic anterior shoulder instability. *Arthroscopy* 2003; 19: 732–739.
3. Griffith JF, Antonio GE, Tong CWC, et al. Anterior shoulder dislocation: quantification of glenoid bone loss with CT. *AJR Am J Roentgenol* 2003; 180: 1423–1430.
4. Itoi E, Lee S-B, Amrami KK, et al. Quantitative assessment of classic anteroinferior bony Bankart lesions by radiography and computed tomography. *Am J Sports Med* 2003; 31: 112–118.
5. Itoi E, Lee SB, Berglund LJ, et al. The effect of a glenoid defect on anteroinferior stability of the shoulder after Bankart repair: a cadaveric study. *J Bone Joint Surg Am* 2000; 82: 35–46.
6. Yamamoto N and Itoi E. Osseous defects seen in patients with anterior shoulder instability. *Clin Orthop Surg* 2015; 7: 425–429.
7. Trivedi S, Pomerantz ML, Gross D, et al. Shoulder instability in the setting of bipolar (glenoid and humeral head) bone loss: the glenoid track concept. *Clin Orthop Relat Res* 2014; 472: 2352–2362.
8. Shin S-J, Koh YW, Bui C, et al. What is the critical value of glenoid bone loss at which soft tissue Bankart repair does not restore glenohumeral translation, restricts range of motion, and leads to abnormal humeral head position? *Am J Sports Med* 2016; 44: 2784–2791.



9. Gottschalk LJ 4th, Walia P, Patel RM, et al. Stability of the glenohumeral joint with combined humeral head and glenoid defects: a cadaveric study. *Am J Sports Med* 2016; 44: 933–940.
10. Weng P-W, Shen H-C, Lee H-H, et al. Open reconstruction of large bony glenoid erosion with allogeneic bone graft for recurrent anterior shoulder dislocation. *Am J Sports Med* 2009; 37: 1792–1797.
11. Warner JJP, Gill TJ, O'hollerhan JD, et al. Anatomical glenoid reconstruction for recurrent anterior glenohumeral instability with glenoid deficiency using an autogenous tricortical iliac crest bone graft. *Am J Sports Med* 2006; 34: 205–212.
12. Cowling PD, Akhtar MA and Liow RYL. What is a Bristow-Latarjet procedure? A review of the described operative techniques and outcomes. *Bone Joint J* 2016; 98-B: 1208–1214.
13. Beran MC, Donaldson CT and Bishop JY. Treatment of chronic glenoid defects in the setting of recurrent anterior shoulder instability: a systematic review. *J Shoulder Elbow Surg* 2010; 19: 769–780.
14. Shah AA, Butler RB, Romanowski J, et al. Short-term complications of the Latarjet procedure. *J Bone Joint Surg Am* 2012; 94: 495–501.
15. Delaney RA, Freehill MT, Janfaza DR, et al. 2014 Neer Award Paper: neuromonitoring the Latarjet procedure. *J Shoulder Elbow Surg* 2014; 23: 1473–1480.
16. Dumont GD, Fogerty S, Rosso C, et al. The arthroscopic Latarjet procedure for anterior shoulder instability: 5-year minimum follow-up. *Am J Sports Med* 2014; 42: 2560–2566.
17. Griesser MJ, Harris JD, McCoy BW, et al. Complications and re-operations after Bristow-Latarjet shoulder stabilization: a systematic review. *J Shoulder Elbow Surg* 2013; 22: 286–292.
18. Dines JS, Dodson CC, McGarry MH, et al. Contribution of osseous and muscular stabilizing effects with the Latarjet procedure for anterior instability without glenoid bone loss. *J Shoulder Elbow Surg* 2013; 22: 1689–1694.
19. Degen RM, Giles JW, Boons HW, et al. A biomechanical assessment of superior shoulder translation after reconstruction of anterior glenoid bone defects: the Latarjet procedure versus allograft reconstruction. *Int J Shoulder Surg* 2013; 7: 7–13.
20. Provencher MT, Ghodadra N, LeClere L, et al. Anatomic osteochondral glenoid reconstruction for recurrent glenohumeral instability with glenoid deficiency using a distal tibia allograft. *Arthroscopy* 2009; 25: 446–452.
21. Tokish JM, Fitzpatrick K, Cook JB, et al. Arthroscopic distal clavicular autograft for treating shoulder instability with glenoid bone loss. *Arthrosc Tech* 2014; 3: e475–e481.
22. Kwapisz A, Fitzpatrick K, Cook JB, et al. Distal clavicular osteochondral autograft augmentation for glenoid bone loss: a comparison of radius of restoration versus Latarjet graft. *Am J Sports Med* 2018; 46: 1046–1052.
23. Harris RI, Vu DH, Sonabend DH, et al. Anatomic variance of the coracoclavicular ligaments. *J Shoulder Elbow Surg* 2001; 10: 585–588.
24. Petersen SA, Bernard JA, Langdale ER, et al. Autologous distal clavicle versus autologous coracoid bone grafts for restoration of anterior-inferior glenoid bone loss: a biomechanical comparison. *J Shoulder Elbow Surg* 2016; 25: 960–966.
25. Young AA, Maia R, Berhouet J, et al. Open Latarjet procedure for management of bone loss in anterior instability of the glenohumeral joint. *J Shoulder Elbow Surg* 2011; 20: S61–S69.
26. Churchill RS, Brems JJ and Kotschi H. Glenoid size, inclination, and version: an anatomic study. *J Shoulder Elbow Surg* 2001; 10: 327–332.
27. Patel RM, Walia P, Gottschalk L, et al. The effects of Latarjet reconstruction on glenohumeral kinematics in the presence of combined bony defects: a cadaveric model. *Am J Sports Med* 2016; 44: 1818–1824.
28. de Beer JF and Roberts C. Glenoid bone defects – open Latarjet with congruent arc modification. *Orthop Clin North Am* 2010; 41: 407–415.
29. Boons HW, Giles JW, Elkinson I, et al. Classic versus congruent coracoid positioning during the Latarjet procedure: an in vitro biomechanical comparison. *Arthroscopy* 2013; 29: 309–316.
30. Giles JW, Puskas G, Welsh M, et al. Do the traditional and modified Latarjet techniques produce equivalent reconstruction stability and strength? *Am J Sports Med* 2012; 40: 2801–2807.
31. McMinn R. *Last's anatomy regional and applied*, 9th ed. London: Churchill Livingstone, 2003.
32. Degen RM, Camp CL, Werner BC, et al. Trends in bone-block augmentation among recently trained orthopaedic surgeons treating anterior shoulder instability. *J Bone Joint Surg Am* 2016; 98: e56.
33. Zhu Y-M, Jiang C-Y, Lu Y, et al. Coracoid bone graft resorption after Latarjet procedure is underestimated: a new classification system and a clinical review with computed tomography evaluation. *J Shoulder Elbow Surg* 2015; 24: 1782–1788.
34. Kay SP, Dragoo JL and Lee R. Long-term results of arthroscopic resection of the distal clavicle with concomitant subacromial decompression. *Arthroscopy* 2003; 19: 805–809.
35. Martin SD, Baumgarten TE and Andrews JR. Arthroscopic resection of the distal aspect of the clavicle with concomitant subacromial decompression. *J Bone Joint Surg Am* 2001; 83-A: 328–335.
36. Taverna E, D'Ambrosi R, Perfetti C, et al. Arthroscopic bone graft procedure for anterior inferior glenohumeral instability. *Arthrosc Tech* 2014; 3: e653–e660.
37. Chapovsky F and Kelly JD 4th. Osteochondral allograft transplantation for treatment of glenohumeral instability. *Arthroscopy* 2005; 21: 1007.
38. Lafosse L, Bongiorno V, Schwartz DG. Arthroscopic Latarjet Procedure. In: Milano G, Grasso A. *Shoulder Arthroscopy: Principles and Practice* (1st ed). New York: Springer; 2014, pp. 451–459.

39. De Beer J, Med M, Burkhart SS, et al. The congruent-arc Latarjet. *Tech Shoulder Elb Surg* 2009; 10: 62–67.
40. Giles JW, Boons HW, Elkinson I, et al. Does the dynamic sling effect of the Latarjet procedure improve shoulder stability? A biomechanical evaluation. *J Shoulder Elbow Surg* 2013; 22: 821–827.
41. Wellmann M, Petersen W, Zantop T, et al. Open shoulder repair of osseous glenoid defects: biomechanical effectiveness of the Latarjet procedure versus a contoured structural bone graft. *Am J Sports Med* 2009; 37: 87–94.
42. Dumont GD, Vopat BG, Parada S, et al. Traditional versus congruent arc Latarjet technique: effect on surface area for union and bone width surrounding screws. *Arthroscopy* 2016; 33: 946–952.
43. Mahakkanukrauh P and Surin P. Prevalence of osteophytes associated with the acromion and acromioclavicular joint. *Clin Anat* 2003; 16: 506–510.
44. Lian J, Dong L, Zhao Y, et al. Anatomical study of the coracoid process in Mongolian male cadavers using the Latarjet procedure. *J Orthop Surg Res* 2016; 11: 126.