



ELSEVIER

## ORIGINAL ARTICLE

# Nonoperative management versus reverse shoulder arthroplasty for treatment of 3- and 4-part proximal humeral fractures in older adults

Troy A. Roberson, MD<sup>a</sup>, Charles M. Granade, PharmD<sup>b</sup>, Quinn Hunt, BS<sup>b</sup>, James T. Griscom, BS<sup>b</sup>, Kyle J. Adams, BS<sup>c</sup>, Amit M. Momaya, MD<sup>a</sup>, Adam Kwapisz, MD<sup>c</sup>, Michael J. Kissenberth, MD<sup>a</sup>, Stefan J. Tolan, MD<sup>a</sup>, Richard J. Hawkins, MD<sup>a</sup>, John M. Tokish, MD<sup>a,\*</sup>

<sup>a</sup>Steadman Hawkins Clinic of the Carolinas, Greenville, SC, USA

<sup>b</sup>School of Medicine, University of South Carolina, Greenville, SC, USA

<sup>c</sup>Hawkins Foundation, Greenville, SC, USA

**Background:** The treatment of 3- and 4-part proximal humeral fractures in the older adult is controversial. No study has directly compared reverse shoulder arthroplasty (RSA) with nonoperative treatment for these fractures. The purpose of this study was to compare clinical and patient-reported outcomes between RSA and nonoperative treatment groups.

**Methods:** A retrospective review was performed on all 3- and 4-part proximal humeral fractures treated with either RSA or nonoperative treatment with minimum 1-year follow-up. All patients in the nonoperative cohort were offered RSA but declined. Objective patient data were obtained from medical records. Patient-reported outcomes including visual analog scale score, Single Assessment Numeric Evaluation score, Penn Shoulder Score, American Shoulder and Elbow Surgeons score, resiliency score, and Veterans Rand-12 scores were obtained at follow-up. Statistical analysis was performed by use of the Student *t* test for continuous variables and  $\chi^2$  analysis for nonparametric data.

**Results:** We analyzed 19 nonoperative and 20 RSA patients with a mean follow-up period greater than 2 years (29 months in nonoperative group and 53 months in RSA group). There were no differences in range of motion between groups (forward elevation, 120° vs 119° [*P* = .87]; external rotation, 23° vs 31° [*P* = .06]). No differences between the nonoperative and RSA groups were noted for any patient-reported outcomes. Among patients receiving RSA, there was no difference in outcomes in those undergoing surgery less than 30 days after injury versus those receiving delayed RSA.

**Conclusions:** This study suggests that there are minimal benefits of RSA over nonoperative treatment for 3- and 4-part proximal humeral fractures in older adults.

**Level of evidence:** Level III; Retrospective Cohort Design; Treatment Study

© 2017 Journal of Shoulder and Elbow Surgery Board of Trustees. All rights reserved.

**Keywords:** Proximal humeral fracture; reverse shoulder arthroplasty; older adult; nonoperative treatment; complications; patient-reported outcomes

Institutional review board approval for this project was received from Greenville Health System (No. Pro00040469).

\*Reprint requests: John M. Tokish, MD, 200 Patewood Dr, Ste C-100, Greenville, SC 29615, USA.

E-mail address: [Jtokish@ghs.org](mailto:Jtokish@ghs.org) (J.M. Tokish).

Proximal humeral fractures pose a significant challenge in the orthopedic community, with an annual incidence of 6 per 10,000 persons in the United States.<sup>22</sup> These fractures commonly present as fragility fractures in older adults,<sup>33</sup> and US census data project a continued rise in this aging population over the next 2 decades, with an even more dramatic increase worldwide.<sup>19,38</sup> The societal and economic burden of this injury is felt not only in the reduction in quality of life but also in the use of available health care resources.<sup>43</sup> The most common treatment modalities for these fragility fractures include nonoperative treatment, open reduction–internal fixation (ORIF), hemiarthroplasty (HA), or reverse shoulder arthroplasty (RSA).

When considering surgical treatment in older adults, 3- and 4-part fractures are the most common indications.<sup>36</sup> However, operative treatment with ORIF can result in a high complication rate.<sup>45</sup> These concerns over complications have led some investigators to question whether the benefit of ORIF is worth the risk, with multiple systematic reviews of randomized controlled trials suggesting no difference in outcomes between nonoperative treatment and ORIF in older patients with 3- and 4-part fractures.<sup>27,30,40</sup>

In addition to ORIF, HA is a common treatment for displaced 3- and 4-part fractures in older adults for many investigators.<sup>16</sup> HA is proposed as an alternative to bypass the concerns of bone quality pertaining to ORIF; some investigators have reported acceptable overall outcomes,<sup>25,34,39,42</sup> whereas others have reported less optimal results.<sup>3,35,55</sup> In a systematic review of HA for 3- and 4-part proximal humeral fractures in nearly all cases, Kontakis et al<sup>24</sup> found relatively good relief of pain but poor range of motion (ROM). In regard to functional outcomes, the mean Constant score was 57, with only 40% of patients achieving either an excellent or satisfactory outcome according to Neer.<sup>36</sup> One explanation for these results is malunion or nonunion of the tuberosities.<sup>5,31</sup> Two randomized controlled trials have compared HA with nonoperative treatment in older patients,<sup>6,37</sup> finding no difference in functional outcome scores and a modest increase in health-related quality of life (HRQoL) in one of the studies.<sup>37</sup> High complication rates and concern over tuberosity malposition and nonunion have led to the increased use of RSA in this population.<sup>17,44</sup> One study has shown improved elevation, external rotation, and internal rotation after tuberosity repair,<sup>13</sup> but another has found function to be independent of tuberosity healing.<sup>46</sup> Studies directly comparing RSA with HA have shown RSA to provide superior ROM,<sup>2,8,9,14,46</sup> improved pain,<sup>2,46</sup> and overall improved functional outcomes<sup>2,7-9,13,14,46,47</sup> in the treatment of proximal humeral fractures. However, to date, no studies have directly compared RSA with nonoperative treatment for proximal humeral fractures in the older adult. Therefore, this study was performed to compare nonoperative treatment with RSA for displaced 3- and 4-part proximal humeral fractures in older adults in relation to complications, ROM, and patient-reported outcomes.

## Methods

A retrospective review was performed on all RSAs performed over a 7-year period (2007–2014) at a single institution. Institutional records were similarly queried for all nonoperatively treated displaced 3- and 4-part proximal humeral fractures over the same period. Plain radiographs and advanced imaging when available were reviewed by 2 orthopedic surgeons to identify 3- and 4-part fractures as defined by Neer<sup>36</sup> for inclusion in the groups. The nonoperative group comprised patients with displaced 3- and 4-part proximal humeral fractures who met surgical indications as per the surgeon's discretion and were offered RSA but elected to undergo nonoperative treatment. The RSA group comprised patients with displaced 3- and 4-part proximal humeral fractures who underwent RSA.

All operations were performed by 1 of 4 fellowship-trained shoulder surgeons. The patients were positioned in the beach-chair position. A standard deltopectoral approach was used to enter the shoulder joint. Two implant systems were used: Reverse Shoulder Prosthesis (DJO Surgical, Austin, TX, USA) or Reverse Shoulder System (Zimmer, Warsaw, IN, USA). The glenoid baseplate was placed as per manufacturer recommendations. It was placed inferiorly on the glenoid and with an inferior tilt to minimize scapular notching.

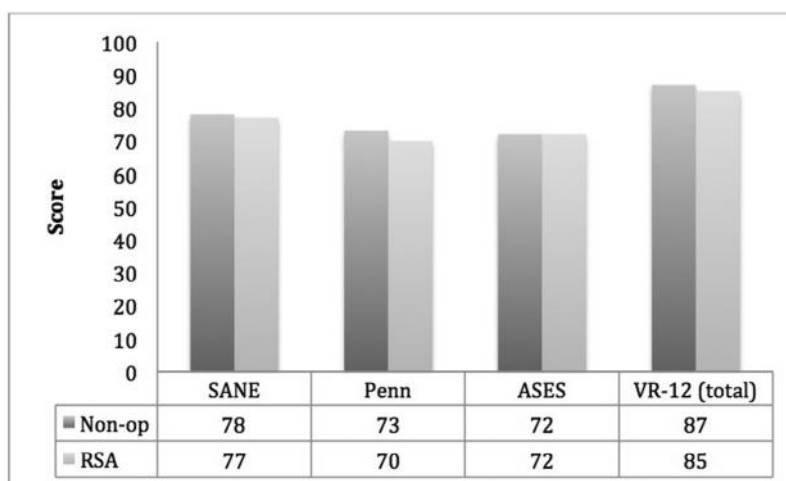
Both nonoperative and RSA patients underwent supervised physical therapy with an emphasis on early ROM with progressive strengthening. Specifically, in patients in the nonoperative group, sling use was maintained for the first 2 weeks. After 2 weeks, patients started a physical therapy protocol in which they started with Codman exercises and passive ROM with forward elevation and abduction. After 6 weeks, patients no longer used the sling and progressed to full active and passive ROM without restrictions. Both groups were allowed to return to full activity without restriction at 3 months.

Medical records were reviewed for patient demographic characteristics, complications, reoperations, and ROM measurements. The overall burden of comorbidities was compared between groups with the respective Charlson comorbidity indices, and patients' self-perceived reaction to adversity was assessed with resiliency scores measured via the Brief Resilience Scale.<sup>50</sup> Complications were defined as an adverse event directly related to the treatment choice, and reoperation was defined as any subsequent surgical intervention related to the index procedure.

Functional outcomes recorded for both groups included ROM measurements and patient-reported outcomes including visual analog scale score, Single Assessment Numeric Evaluation score, Penn Shoulder Score (PSS), and American Shoulder and Elbow Surgeons (ASES) score. HRQoL was assessed with the Veterans Rand-12 (VR-12) physical and mental component scores, which were obtained at a minimum of 1 year from the time of injury. Patients undergoing RSA were further analyzed by the timing of RSA: early (<30 days) versus delayed. Patients in the delayed group either presented to the treating surgeon beyond 30 days from injury or declined surgery and changed their minds requesting surgery after 30 days. Statistical analysis was performed by use of the Student *t* test for continuous variables and  $\chi^2$  analysis for nonparametric data, with  $P < .05$  considered significant.

## Results

In total, 39 patients were identified with 3- and 4-part proximal humeral fractures, with 20 in the RSA group and 19 in the nonoperative group, at a mean follow-up of greater than 2 years (29 months in nonoperative group and 53 months in



**Figure 1** Patient-reported outcome scores for nonoperative treatment (Non-op) versus reverse shoulder arthroplasty (RSA) for 3- and 4-part proximal humeral fractures. ASES, American Shoulder and Elbow Surgeons score; Penn, Penn Shoulder Score; SANE, Single Assessment Numeric Evaluation score.

**Table I** Patient characteristics in nonoperative group versus RSA group

	Nonoperative treatment	RSA	<i>P</i> value
n	19	20	
Age, y	71	71	.71
Gender	4 M and 15 F	1 M and 19 F	.13
Charlson comorbidity index	1.7	1.3	.48
Follow-up, mo	29	53	.05
Reoperation*	0	3 (15%)	.08

F, female; M, male; RSA, reverse shoulder arthroplasty.

\*Reoperations comprised 1 open reduction, 1 scar débridement, and 1 débridement and irrigation.

RSA group,  $P < .05$ ). There was no difference in fracture classification between groups ( $P = .77$ ), and the mean age was 71 years (range, 52-88 years) at the time of injury with no difference between treatment groups ( $P = .71$ ). No differences in gender ( $P = .13$ ), Charlson comorbidity index ( $P = .48$ ), or resiliency ( $P = .14$ ) were noted between groups (Table I).

In the nonoperative group, there were 15 three-part and 4 four-part fractures. Specific parameters not included in the Neer classification involved 3 fractures with greater than 50% displacement of the shaft in relation to the head and 3 fractures with head splits. In the RSA group, there were 15 three-part and 5 four-part fractures. Specific parameters not included in the Neer classification involved 5 fractures with greater than 50% displacement of the shaft in relation to the head, 1 fracture with a head split, and 2 fracture-dislocations.

There were no subsequent operative procedures in the nonoperative group during the follow-up period. Three patients in the RSA group had complications, all of which resulted in reoperations. These reoperations included open reduction for dislocation of RSA, débridement and irrigation for infection, and arthroscopic lysis of adhesions for intractable

stiffness. The ASES, PSS, and VR-12 scores for these patients were notably lower but did not reach statistical significance, whereas forward elevation was significantly lower compared with the overall RSA group at final follow-up ( $80^\circ$  vs  $119^\circ$ ,  $P < .05$ ).

There was no statistical difference in final ROM in the nonoperative group versus the RSA group in forward elevation ( $120^\circ$  vs  $119^\circ$ ,  $P = .87$ ) and external rotation ( $23^\circ$  vs  $31^\circ$ ,  $P = .06$ ). No difference was noted in the nonoperative group versus the RSA group for any patient-reported outcome (Single Assessment Numeric Evaluation score, 78 vs 77 [ $P = .90$ ]; PSS, 73 vs 70 [ $P = .70$ ]; ASES score, 72 vs 72 [ $P = .99$ ]; visual analog scale score, 1.1 vs 1.5 [ $P = .51$ ]) (Fig. 1). There was also no difference in HRQoL in the nonoperative group versus the RSA group (VR-12 physical component score, 35 vs 38 [ $P = .44$ ]; VR-12 mental component score, 52 vs 47 [ $P = .35$ ]) (Table II). When we compared RSA patients who underwent early (<30 days) versus delayed operative treatment, there were no differences in ROM, patient-reported outcomes, or total HRQoL. However, the delayed group had a lower score for the physical component of the VR-12 when compared with the early RSA group (Table III).

## Discussion

The treatment of complex proximal humeral fractures in older adults remains a challenge. A recent randomized clinical trial in the United Kingdom<sup>41</sup> and a recent Cochrane review<sup>18</sup> have shown no difference in outcomes between combined surgical treatment and nonoperative management in proximal humeral fractures, leaving some investigators to question the role of surgical treatment in these fractures. No studies have ever directly compared nonoperative management with RSA for the treatment of 3- and 4-part proximal humeral fractures in the older adult. Our study suggests that there are no benefits of RSA over nonoperative treatment for 3- and 4-part

**Table II** Outcomes of proximal humeral fractures undergoing nonoperative treatment versus RSA

	Nonoperative treatment	RSA	P value
Range of motion			
Forward elevation, °	120	119	.87
External rotation, °	23	31	.06
Patient-reported outcomes			
SANE	78	77	.90
Penn Shoulder Score	73	70	.70
ASES score	72	72	.99
Resiliency score	22	20	.14
VR-12 score			
Total	87	85	.81
PCS	35	38	.44
MCS	52	47	.35
VAS score	1.1	1.5	.51

ASES, American Shoulder and Elbow Surgeons; MCS, mental component score; PCS, physical component score; RSA, reverse shoulder arthroplasty; SANE, Single Assessment Numeric Evaluation; VAS, visual analog scale.

**Table III** Outcomes of early RSA (<30 days) versus delayed RSA

	Early	Delayed	P value
Range of motion			
Forward elevation, °	114	138	.09
External rotation, °	32	28	.38
Patient-reported outcomes			
SANE score	77	76	.94
Penn Shoulder Score	69	70	.96
ASES score	71	75	.76
Resiliency score	19	20	.83
VR-12 score			
Total	87	76	.46
PCS	40	24	.05
MCS	46	52	.68
VAS score	2	1.3	.80

ASES, American Shoulder and Elbow Surgeons; MCS, mental component score; PCS, physical component score; RSA, reverse shoulder arthroplasty; SANE, Single Assessment Numeric Evaluation; VAS, visual analog scale.

proximal humeral fractures in the older adult with regard to ROM and patient-reported outcomes.

Nonoperative treatment is generally accepted to result in a notable decrease in ROM, with one systematic review of all fracture grades reporting limitations to 139° of forward flexion and 48° of external rotation at an average age of 65 years.<sup>20</sup> However, when only 3- and 4-part fractures are considered and when multiple studies are combined, less desirable ROM has been reported, with pooled average forward flexion to 113° and external rotation to 43°. <sup>11,53,54</sup> A similar trend in Constant scores has been found, with the same systematic review of all fracture types<sup>20</sup> reporting an average Constant score of 74 whereas studies of 3- and 4-part fractures reported an average of approximately 60.<sup>6,52,53</sup> This has led many investigators to consider 3- and 4-part fractures as indications for surgical management.

However, the literature has failed to show a clear advantage for operative treatment in this category.<sup>6,27,30,37,40</sup> With complication rates of these surgical treatments ranging from 10% to 29%<sup>15,27</sup> and worse outcomes with revision surgery after conversion from previous surgical treatment,<sup>21</sup> many investigators have moved toward RSA in hope of a reliable surgical option. Multiple studies have reported results after RSA for proximal humeral fractures, with a systematic review of studies through early 2013 reporting a weighted mean ASES score of 74, Constant score of 56, and forward elevation of 122° with external rotation of 18°. <sup>1</sup> This systematic review did not discriminate by fracture classification, but in a comparison of the included studies specifically for complex or 3- and 4-part fractures<sup>12,23,28,29,51</sup> combined with more recent reports<sup>8,9</sup> of the same fracture classification, the weighted mean ASES and Constant scores were 76 and 57, respectively, whereas forward elevation and external rotation were 129° and 19°, respectively.

Overall, these results are comparable with those of the RSA group in our study with regard to patient-reported outcomes and ROM values. The mean ASES score was 72 in our RSA group, which is similar to that reported in the previously mentioned studies. The complication rate of 15% in our study likewise is in line with previous reports of RSA for proximal humeral fractures.<sup>1,32</sup>

A specific concern regarding management of complex proximal humeral fractures is whether delaying surgical treatment may alter outcomes. This study found no substantial differences between early and delayed RSA with the exception of the physical component of the VR-12 score. This overall finding is in agreement with the findings of Dezfuli et al,<sup>10</sup> who reported no differences in patient-reported outcomes or ROM after acute RSA versus delayed RSA for malunion or nonunion. These results suggest that although delayed RSA may present a technical challenge, outcomes are not compromised and nearly all proximal humeral fractures in the older adult may be given a trial of nonoperative management without fear of compromising the results of a delayed RSA.

A potential criticism of this study is that the patients who proceed with RSA may be fundamentally different from those patients who elect to undergo nonoperative treatment. Nonetheless, in this study there were no differences between the groups in age, gender, Charlson comorbidity index, or fracture classification. In addition, there were no differences in resiliency, an indicator of a patient's overall ability to respond to adversity.

This study is not without limitations. A weakness of the study concerns the reliability of the classification system used. The Neer classification is the most widely used and accepted grading system for proximal humeral fractures and is commonly used to report results after treatment of these fractures. However, multiple studies have shown the reliability of the Neer classification to be less than desirable.<sup>4,26,48,49</sup> Nonetheless, given that reporting using this classification system is commonplace, we considered this the best option for comparison in the literature. There also was a difference in the overall length of follow-up in the nonoperative and RSA

groups. Although the mean follow-up of both groups was well over 2 years, follow-up in the RSA group averaged more than 4 years. We allowed a minimum 1-year follow-up for the nonoperative group because in our clinical experience, without surgical aftercare, a nonoperatively treated proximal humeral fracture most commonly achieves maximum clinical improvement within 1 year of injury. Finally, there remains the potential for selection bias. The surgeon may have more strongly suggested RSA to patients with severe 3- and 4-part fractures. Nonetheless, all patients included were patients in whom the surgeon felt RSA was indicated, and thus arthroplasty was offered to all patients in this cohort.

When considering surgical treatment, the greatest burden is proof of benefit over the natural history of the injury itself with an acceptable tradeoff of complications. To date, no such comparison exists in the literature, and the greatest strength of our study is the addition to the literature of a direct comparison of nonoperative treatment with RSA for 3- and 4-part proximal humeral fractures in the older adult. In this comparison, we found no clear benefit of RSA over nonoperative management, with the RSA group exhibiting a significantly higher reoperation rate. These results should serve as a baseline from which future prospective studies with larger cohorts may further examine the role of RSA in proximal humeral fractures in the older adult. Future studies should evaluate whether RSA may afford patients an earlier return to function.

## Conclusions

This is the first study to compare nonoperative management versus RSA in the treatment of displaced 3- and 4-part fractures of the proximal humerus in the older adult. This study suggests that there are no clinical benefits in early-term to midterm follow-up of RSA over nonoperative treatment. In addition, no differences were noted for those patients who received RSA in a delayed fashion, suggesting a trial of nonoperative management will not compromise the outcomes of a delayed RSA.

## Disclaimer

The authors, their immediate families, and any research foundations with which they are affiliated have not received any financial payments or other benefits from any commercial entity related to the subject of this article.

## References

- Anakwenze OA, Zoller S, Ahmad CS, Levine WN. Reverse shoulder arthroplasty for acute proximal humerus fractures: a systematic review. *J Shoulder Elbow Surg* 2014;23:e73-80. <http://dx.doi.org/10.1016/j.jse.2013.09.012>
- Baudi P, Campochiaro G, Serafini F, Gazzotti G, Matino G, Rovesta C, et al. Hemiarthroplasty versus reverse shoulder arthroplasty: comparative study of functional and radiological outcomes in the treatment of acute proximal humerus fracture. *Musculoskelet Surg* 2014;98(Suppl 1):19-25. <http://dx.doi.org/10.1007/s12306-014-0322-3>
- Becker R, Pap G, Machner A, Neumann WH. Strength and motion after hemiarthroplasty in displaced four-fragment fracture of the proximal humerus: 27 patients followed for 1-6 years. *Acta Orthop Scand* 2002;73:44-9. <http://dx.doi.org/10.1080/000164702317281396>
- Bernstein J, Adler LM, Blank JE, Dalsey RM, Williams GR, Iannotti JP. Evaluation of the Neer system of classification of proximal humeral fractures with computerized tomographic scans and plain radiographs. *J Bone Joint Surg Am* 1996;78:1371-5.
- Boileau P, Krishnan SG, Tinsi L, Walch G, Coste JS, Molé D. Tuberosity malposition and migration: reasons for poor outcomes after hemiarthroplasty for displaced fractures of the proximal humerus. *J Shoulder Elbow Surg* 2002;11:401-12. <http://dx.doi.org/10.1067/mse.2002.124527>
- Boons HW, Goosen JH, van Grinsven S, van Susante JL, van Loon CJ. Hemiarthroplasty for humeral four-part fractures for patients 65 years and older: a randomized controlled trial. *Clin Orthop Relat Res* 2012;470:3483-91. <http://dx.doi.org/10.1007/s11999-012-2531-0>
- Boyle MJ, Youn SM, Frampton CM, Ball CM. Functional outcomes of reverse shoulder arthroplasty compared with hemiarthroplasty for acute proximal humeral fractures. *J Shoulder Elbow Surg* 2013;22:32-7. <http://dx.doi.org/10.1016/j.jse.2012.03.006>
- Chalmers PN, Slikker W, Mall NA, Gupta AK, Rahman Z, Enriquez D, et al. Reverse total shoulder arthroplasty for acute proximal humeral fracture: comparison to open reduction-internal fixation and hemiarthroplasty. *J Shoulder Elbow Surg* 2014;23:197-204. <http://dx.doi.org/10.1016/j.jse.2013.07.044>
- Cuff DJ, Pupello DR. Comparison of hemiarthroplasty and reverse shoulder arthroplasty for the treatment of proximal humeral fractures in elderly patients. *J Bone Joint Surg Am* 2013;95:2050-5. <http://dx.doi.org/10.2106/JBJS.L.01637>
- Dezfuli B, King JJ, Farmer KW, Struk AM, Wright TW. Outcomes of reverse total shoulder arthroplasty as primary versus revision procedure for proximal humerus fractures. *J Shoulder Elbow Surg* 2016;25:1133-7. <http://dx.doi.org/10.1016/j.jse.2015.12.002>
- Edelson G, Kelly I, Vigder F, Reis ND. A three-dimensional classification for fractures of the proximal humerus. *J Bone Joint Surg Br* 2004;86:413-25. <http://dx.doi.org/10.1302/0301-620X.86B3.14428>
- Gallinet D, Adam A, Gasse N, Rochet S, Obert L. Improvement in shoulder rotation in complex shoulder fractures treated by reverse shoulder arthroplasty. *J Shoulder Elbow Surg* 2013;22:38-44. <http://dx.doi.org/10.1016/j.jse.2012.03.011>
- Gallinet D, Clappaz P, Garbuio P, Tropet Y, Obert L. Three or four parts complex proximal humerus fractures: hemiarthroplasty versus reverse prosthesis: a comparative study of 40 cases. *Orthop Traumatol Surg Res* 2009;95:48-55. <http://dx.doi.org/10.1016/j.otsr.2008.09.002>
- Garrigues GE, Johnston PS, Pepe MD, Tucker BS, Ramsey ML, Austin LS. Hemiarthroplasty versus reverse total shoulder arthroplasty for acute proximal humerus fractures in elderly patients. *Orthopedics* 2012;35:e703-8. <http://dx.doi.org/10.3928/01477447-20120426-25>
- Gupta AK, Harris JD, Erickson BJ, Abrams GD, Bruce B, McCormick F, et al. Surgical management of complex proximal humerus fractures—a systematic review of 92 studies including 4500 patients. *J Orthop Trauma* 2015;29:54-9. <http://dx.doi.org/10.1097/BOT.0000000000000229>
- Guy P, Slobogean GP, McCormack RG. Treatment preferences for displaced three- and four-part proximal humerus fractures. *J Orthop Trauma* 2010;24:250-4. <http://dx.doi.org/10.1097/BOT.0b013e3181bdc46a>
- Han RJ, Sing DC, Feeley BT, Ma CB, Zhang AL. Proximal humerus fragility fractures: recent trends in nonoperative and operative treatment in the Medicare population. *J Shoulder Elbow Surg* 2016;25:256-61. <http://dx.doi.org/10.1016/j.jse.2015.07.015>
- Handoll HH, Brorson S. Interventions for treating proximal humeral fractures in adults. *Cochrane Database Syst Rev* 2015;(11):CD000434. <http://dx.doi.org/10.1002/14651858.CD000434.pub4>

19. He W, Goodkind D, Kowal P. An aging world: 2015. Suitland, MD: US Census Bureau; 2016. International Population Reports, 95/16-1.
20. Iyengar JJ, Devic Z, Sproul RC, Feeley BT. Nonoperative treatment of proximal humerus fractures: a systematic review. *J Orthop Trauma* 2011;25:612-7. <http://dx.doi.org/10.1097/BOT.0b013e3182008df8>
21. Jost B, Spross C, Grehn H, Gerber C. Locking plate fixation of fractures of the proximal humerus: analysis of complications, revision strategies and outcome. *J Shoulder Elbow Surg* 2013;22:542-9. <http://dx.doi.org/10.1016/j.jse.2012.06.008>
22. Karl JW, Olson PR, Rosenwasser MP. The epidemiology of upper extremity fractures in the United States, 2009. *J Orthop Trauma* 2015;29:e242-4. <http://dx.doi.org/10.1097/BOT.0000000000000312>
23. Klein M, Juschka M, Hinkenjann B, Scherger B, Ostermann PA. Treatment of comminuted fractures of the proximal humerus in elderly patients with the Delta III reverse shoulder prosthesis. *J Orthop Trauma* 2008;22:698-704. <http://dx.doi.org/10.1097/BOT.0b013e31818afe40>
24. Kontakis G, Koutras C, Tosounidis T, Giannoudis P. Early management of proximal humeral fractures with hemiarthroplasty: a systematic review. *J Bone Joint Surg Br* 2008;90:1407-13. <http://dx.doi.org/10.1302/0301-620X.90B11.21070>
25. Kralinger F, Schwaiger R, Wambacher M, Farrell E, Menth-Chiari W, Lajtai G, et al. Outcome after primary hemiarthroplasty for fracture of the head of the humerus. A retrospective multicentre study of 167 patients. *J Bone Joint Surg Br* 2004;86:217-9. <http://dx.doi.org/10.1302/0301-620X.86B2.14553>
26. Kristiansen B, Andersen UL, Olsen CA, Varmarken JE. The Neer classification of fractures of the proximal humerus. An assessment of interobserver variation. *Skeletal Radiol* 1988;17:420-2.
27. Launonen AP, Lepola V, Flinkkilä T, Laitinen M, Paavola M, Malmivaara A. Treatment of proximal humerus fractures in the elderly: a systemic review of 409 patients. *Acta Orthop* 2015;86:280-5. <http://dx.doi.org/10.3109/17453674.2014.999299>
28. Lenarz C, Shishani Y, McCrum C, Nowinski RJ, Edwards TB, Gobezie R. Is reverse shoulder arthroplasty appropriate for the treatment of fractures in the older patient? Early observations. *Clin Orthop Relat Res* 2011;469:3324-31. <http://dx.doi.org/10.1007/s11999-011-2055-z>
29. Levy JC, Badman B. Reverse shoulder prosthesis for acute four-part fracture: tuberosity fixation using a horseshoe graft. *J Orthop Trauma* 2011;25:318-24. <http://dx.doi.org/10.1097/BOT.0b013e3181f22088>
30. Li Y, Zhao L, Zhu L, Li J, Chen A. Internal fixation versus nonoperative treatment for displaced 3-part or 4-part proximal humeral fractures in elderly patients: a meta-analysis of randomized controlled trials. *PLoS One* 2013;8:7. <http://dx.doi.org/10.1371/journal.pone.0075464>
31. Loebenberg MI, Jones DA, Zuckerman JD. The effect of greater tuberosity placement on active range of motion after hemiarthroplasty for acute fractures of the proximal humerus. *Bull Hosp Jt Dis* 2005;62:90-3.
32. Lopiz Y, García-Coiradas J, Serrano-Mateo L, García-Fernández C, Marco F. Reverse shoulder arthroplasty for acute proximal humeral fractures in the geriatric patient: results, health-related quality of life and complication rates. *Int Orthop* 2016;40:771-81. <http://dx.doi.org/10.1007/s00264-015-3085-z>
33. Maravic M, Briot K, Roux C, Collège Français des Médecins Rhumatologues (CFMR). Burden of proximal humerus fractures in the French National Hospital Database. *Orthop Traumatol Surg Res* 2014;100:931-4. <http://dx.doi.org/10.1016/j.otsr.2014.09.017>
34. Mighell MA, Kolm GP, Collinge CA, Frankle MA. Outcomes of hemiarthroplasty for fractures of the proximal humerus. *J Shoulder Elbow Surg* 2003;12:569-77. [http://dx.doi.org/10.1016/S1058-2746\(03\)00213-1](http://dx.doi.org/10.1016/S1058-2746(03)00213-1)
35. Movin T, Sjöden GO, Ahrengart L. Poor function after shoulder replacement in fracture patients. A retrospective evaluation of 29 patients followed for 2-12 years. *Acta Orthop Scand* 1998;69:392-6.
36. Neer CS. Displaced proximal humeral fractures. II. Treatment of three-part and four-part displacement. *J Bone Joint Surg Am* 1970;52:1090-103.
37. Olerud P, Ahrengart L, Ponzer S, Saving J, Tidermark J. Hemiarthroplasty versus nonoperative treatment of displaced 4-part proximal humeral fractures in elderly patients: a randomized controlled trial. *J Shoulder Elbow Surg* 2011;20:1025-33. <http://dx.doi.org/10.1016/j.jse.2011.04.016>
38. Ortman JM, Velkoff VA, Hogan H. An aging nation: the older population in the United States. Suitland, MD: US Census Bureau; 2014. Current Population Reports, P25-1140.
39. Prakash U, McGurty DW, Dent JA. Hemiarthroplasty for severe fractures of the proximal humerus. *J Shoulder Elbow Surg* 2002;11:428-30. <http://dx.doi.org/10.1067/mse.2002.126615>
40. Rabi S, Evaniew N, Sprague SA, Bhandari M, Slobogean GP. Operative vs non-operative management of displaced proximal humeral fractures in the elderly: a systematic review and meta-analysis of randomized controlled trials. *World J Orthop* 2015;6:838-46. <http://dx.doi.org/10.5312/wjo.v6.i10.838>
41. Rangan A, Handoll H, Brealey S, Jefferson L, Keding A, Martin BC, et al. Surgical vs nonsurgical treatment of adults with displaced fractures of the proximal humerus: the PROFHER randomized clinical trial. *JAMA* 2015;313:1037-47. <http://dx.doi.org/10.1001/jama.2015.1629>
42. Robinson CM, Page RS, Hill RM, Sanders DL, Court-Brown CM, Wakefield AE. Primary hemiarthroplasty for treatment of proximal humeral fractures. *J Bone Joint Surg Am* 2003;85:1215-23.
43. Sabesan VJ, Valikodath T, Childs A, Sharma VK. Economic and social impact of upper extremity fragility fractures in elderly patients. *Aging Clin Exp Res* 2015;27:539-46. <http://dx.doi.org/10.1007/s40520-014-0295-y>
44. Schairer WW, Nwachukwu BU, Lyman S, Craig EV, Gulotta LV. Reverse shoulder arthroplasty versus hemiarthroplasty for treatment of proximal humerus fractures. *J Shoulder Elbow Surg* 2015;24:1560-6. <http://dx.doi.org/10.1016/j.jse.2015.03.018>
45. Schliemann B, Siemoneit J, Theisen C, Kösters C, Weimann A, Raschke MJ. Complex fractures of the proximal humerus in the elderly—outcome and complications after locking plate fixation. *Musculoskelet Surg* 2012;96(Suppl 1):S3-11. <http://dx.doi.org/10.1007/s12306-012-0181-8>
46. Sebastián-Forcada E, Cebrián-Gómez R, Lizaur-Utrilla A, Gil-Guillén V. Reverse shoulder arthroplasty versus hemiarthroplasty for acute proximal humeral fractures. A blinded, randomized, controlled, prospective study. *J Shoulder Elbow Surg* 2014;23:1419-26. <http://dx.doi.org/10.1016/j.jse.2014.06.035>
47. Shukla DR, McAnany S, Kim J, Overley S, Parsons BO. Hemiarthroplasty versus reverse shoulder arthroplasty for treatment of proximal humeral fractures: a meta-analysis. *J Shoulder Elbow Surg* 2016;25:330-40. <http://dx.doi.org/10.1016/j.jse.2015.08.030>
48. Sidor ML, Zuckerman JD, Lyon T, Koval K, Cuomo F, Schoenberg N. The Neer classification system for proximal humeral fractures. An assessment of interobserver reliability and intraobserver reproducibility. *J Bone Joint Surg Am* 1993;75:1745-50.
49. Siebenrock KA, Gerber C. The reproducibility of classification of fractures of the proximal end of the humerus. *J Bone Joint Surg Am* 1993;75:1751-5.
50. Smith BW, Dalen J, Wiggins K, Tooley E, Christopher P, Bernard J. The brief resilience scale: assessing the ability to bounce back. *Int J Behav Med* 2008;15:194-200. <http://dx.doi.org/10.1080/10705500802222972>
51. Valenti P, Katz D, Kilinc A, Elkholti K, Gasiunas V. Mid-term outcome of reverse shoulder prostheses in complex proximal humeral fractures. *Acta Orthop Belg* 2012;78:442-9.
52. Yüksel HY, Yılmaz S, Akşahin E, Celebi L, Muratlı HH, Biçimoğlu A. The results of nonoperative treatment for three- and four-part fractures of the proximal humerus in low-demand patients. *J Orthop Trauma* 2011;25:588-95. <http://dx.doi.org/10.1097/BOT.0b013e318210ea56>
53. Zyto K. Non-operative treatment of comminuted fractures of the proximal humerus in elderly patients. *Injury* 1998;29:349-52.
54. Zyto K, Kronberg M, Broström LA. Shoulder function after displaced fractures of the proximal humerus. *J Shoulder Elbow Surg* 1995;4:331-6.
55. Zyto K, Wallace WA, Frostick SP, Preston BJ. Outcome after hemiarthroplasty for three- and four-part fractures of the proximal humerus. *J Shoulder Elbow Surg* 1998;7:85-9.